e-ISSN: 2321 - 9637
p-ISSN: 2321 - 6379

ISS JOURNAL

IJSS

International Journal of Scientific Study

www.ijss-sn.com

July 2015 - Volume 3 - Issue 4

INTERNATIONAL JOURNAL OF SCIENTIFIC STUDY

Abstracting & Indexing

1. Index Medicus (IMSEAR)
2. Global Index Medicus
3. Index Copernicus
4. Directory of Open Access Journals(DOAJ)
5. Google Scholar
6. WorldCat
7. SafetyLit
8. WHO Hinari
9. Genamics Journal Seek
10. Ulrichsweb Serials Solutions
11. International Committee of Medical Journal Editors(ICJME)
12. Geneva Foundation for Medical Education & Research(GFMER)
13. Socolar
14. Bielefeld Academic Search Engine(BASE)
15. Research Bible
16. Academic Journals Database
17. J-Gate
18. Jour Informatics
19. NISCAIR
20. Directory of Research Journal Indexing(DRJI)
21. Scientific Indexing Services(SIS)
22. Rubriq-Beta
23. SHERPA RoMEO,
24. New Jour
25. E-International Journals of Academic & Scientific Research(EIJASR)
26. IndianScience.in
27. CiteFactor
28. Scientific Journal Impact Factor (SJIF)
29. Journal Index.net
30. RDAD
31. Global Impact Factor(GIF)
32. International Society for Research Activity (ISRA)
33. Advanced Science Index
34. OpenAccessArticles.com

Original Article

DOI: 10.17354/ijss/2015/324

Dimensions of Glenoid Fossa of Scapula: Implications in the Biomechanics of an Implant Design

Ajay Kumar Mahto[1], Saif Omar[2]

[1]Professor, Department of Orthopedics, Katihar Medical College, Katihar, Bihar, India. [2]Associate Professor, Department of Anatomy, Katihar Medical College, Katihar, Bihar, India

Abstract

Introduction: The entire upper extremity is connected to the axial skeleton through the scapula by various strong muscles and two joints, the sternoclavicular and acromioclavicular. The clavicle appears to play the role of a strut that defines the distance between the torso and the scapula. Nevertheless, the true biomechanical function of the clavicle is not clearly understood. Attempts have been made by several authors to understand the shoulder suspension complex and to explain the pathobiomechanics of certain shoulder injuries.

Aim: The aim of the present study was to observe the glenoid fossa of the human scapula.

Materials and Methods: The present study was conducted on eighty dry adult human intact scapulae obtained from the Department of Anatomy of four different medical colleges in the state of Bihar. Dimensions of the glenoid fossa of each in two axes were recorded and compared bilaterally.

Result: Vertical glenoid diameter is higher than horizontal glenoid diameter due to shape and diameters on the right side were larger than those of the left side.

Conclusion: Dimensions of the glenoid fossa are important both surgically and biomechanically, as orthopedicians require the utility of an implant for shoulder arthroplasty. Knowledge of variations of the glenoid cavity is essential for evaluating pathological conditions, osseous lesions and osteochondral defects related to the shoulder joint.

Key words: Arthroplasty, Glenoid fossa, Implant, Scapula

INTRODUCTION

The scapulae are a pair of triangular, large, flat bones that are situated dorsally in the ribcage in relation with the second to seventh ribs. The scapula has three borders, three processes, and three angles. The glenoid (Gk. *Glene* "socket") fossa is oriented at the lateral angle of the bone. During development, the glenoid fossa shows slight concavity at 20 mm crown rump length. The process of scapular development and ossification are extremely variable. Individuals may experience different rates of ossification, and some may never obtain the complete fusion of the scapula with the acromial process (*os acromiale*). The shoulder joint is a synovial joint of ball and socket variety and by virtue of evolution; it has gained mobility at the cost of stability. It is a complex assembly of muscles, tendons, ligaments, cartilages and bones. For the functional integrity of the joint, all these structures should be healthy and must work in accordance with each other. If any one of these structures is diseased or injured, it can have a negative ripple effect on the functioning of the others. The two articulating surfaces of the shoulder joint are the hemispherical head of the humerus and the glenoid fossa of the scapula. The stability of the humeral head on the glenoid fossa is provided by the musculotendinous cuff. The scapula is surrounded by muscles and is further protected from injury by its vicinity to the thoracic wall. In polytrauma

IJSS
www.ijss-sn.com

Month of Submission	05-2015
Month of Peer Review	06-2015
Month of Acceptance	07-2015
Month of Publishing	07-2015

Corresponding Author: Dr. Saif Omar, Associate Professor, Department of Anatomy, Katihar Medical College, Katihar 854 105, Bihar, India. Phone No: +919431229999. E-mail: drsaifomar@gmail.com

patients, fracture of the scapula is an indicator of severe thoracic trauma including occasional rupture of the thoracic aorta. Isolated fractures are rare and are usually due to an isolated blow from the back directly targeting the scapula. Associated ipsilateral fracture of the clavicle may occur in a quarter of the cases and can result in a floating shoulder. Shoulder arthroplasty is a common orthopedic intervention in the clinical management of shoulder arthritis. Compared to fractures of the clavicle and scapula, fracture of the glenoid rim is a completely different entity as it is usually a result of dislocation of the glenohumeral joint. Knowledge of the shape and morphological parameters of both the articulating surfacea is essential for a successful shoulder arthroplasty as otherwise there would be loosening of the joint necessitating revision surgery.[1] The fibrocartilaginous glenoidal labrum can be detached leading to a Bankart's lesion.[2] Surgical treatment in glenohumeral arthritis requires a thorough knowledge of both morphology and morphometry of glenoid fossa especially when a prosthesis has to be used. As no such previous citable research was available in Bihar, this study was taken up with the aim of providing morphometric data for anatomists, anthropologists, forensic experts, and orthopedicians.

MATERIALS AND METHODS

Eighty dry adult human intact scapulae were obtained from four medical colleges in Bihar. Specimens that were malformed or showed signs of previous pathology in any part of the bone were excluded from this study. Sex of the bone was not considered. Bones were bilaterally equal in number. Morphometry of the glenoid fossa was performed using sliding Vernier callipers. Measurements of the glenoid fossa were taken along two different axes; vertical and horizontal. Vertical glenoid diameter (VGD) was taken along the maximum vertical length of the glenoid fossa between its superior and inferior borders. Horizontal glenoid diameter (HGD) was taken along the maximum horizontal breadth of the glenoid fossa around its midpoint between the anterior and posterior borders (Figures 1 and 2)

Observation

The results are well explained in Tabular form. Table 1 gives information about Statistical analysis of bilateral VGD and HG. Along with that Table 2 depicts the Comparison of VGD with other workers and Table 3 provides information about the Comparison of HGD with other workers

DISCUSSION

Anterior dislocation of the shoulder joint is perhaps the commonest of dislocations in the human body and is more

Figure 1: Scapula and sliding Vernier Calliper with 1 mm accuracy

Figure 2: Measurements of the glenoid fossa in two axes. VGD: Vertical glenoid diameter, HGD: Horizontal glenoid diameter

common in adults than in children. It results due to a direct force pushing the head of the humerus out of the glenoid cavity and thereby injuring the latter consequently. Scapular fractures may be related to any of the following: Body, neck, processes, articular fractures, and fractures involving the associated clavicle. Fractures involving the glenoid rim may be treated operatively to restore the joint surface and to avoid long-term instability of the glenohumeral articulation. Shoulder arthritis presents a unique challenge to the orthopedic surgeon as there may be stripping of the glenoidal labrum from the glenoid fossa. Due to the complex anatomy of the concerned region it is relevant to understand the dimensions of the screw and implants to be utilized as they must have access to the posterior cortex in the neck region of the scapula. Total shoulder replacement has often yielded poor results due to eccentric loading of the glenoid leading to loosening and early failure. Multiple procedures have been recommended to solve this problem including total arthroplasty, hemiarthroplasty and

Table 1: Statistical analysis of bilateral VGD and HGD

S. no.	VGD				HGD			
1	R	Mean=3.62 cm	L	Mean=3.32 cm	R	Mean=2.42 cm	L	Mean=2.25 cm
2	R	Range=3.5-3.9	L	Range=3.1-3.6	R	Range=2.3-2.6	L	Range=2.1-2.5
3	R	SD=0.17	L	SD=0.16	R	SD=0.13	L	SD=0.14

R: Right, L: Left, SD: Standard deviation, VGD: Vertical glenoid diameter, HGD: Horizontal glenoid diameter

Table 2: Comparison of VGD with other workers

Authors	Race	Mean (cm)	SD
Coskun	Turkish	3.36	0.4
Piyawinijwong	Thai	3.36	0.31
Von Schroeder	Canadian	3.6	0.4

SD: Standard deviation, VGD: Vertical glenoid diameter

Table 3: Comparison of HGD with other workers

Authors	Race	Mean (cm)	SD
Coskun	Turkish	2.4	0.25
Piyawinijwong	Thai	2.7	0.31
Von Schroeder	Canadian	2.9	0.3

SD: Standard deviation, HGD: Horizontal glenoid diameter

shoulder arthrodesis. For treating the displaced fractures of the glenoid fossa, most authors have recommended open reduction and internal fixation to restore joint congruity and to prevent post-operative arthrosis. The current standard of treatment in shoulder arthritis offers limited goal for functional improvement and only a modest improvement in pain. Glenoid reconstructions using implants may be considered. Morphometric parameters of the glenoid fossa in our study were recorded and statistically analyzed. On the right side, mean VGD and mean HGD were 3.62 and 3.42, respectively. On the left side, mean VGD and mean HGD were 3.32 and 2.25, respectively. Our data obtained is in accordance with the research of previous workers.[1-10] As there are variations in scapular morphology, individualized adjustments may be required for reverse shoulder prostheses.

CONCLUSION

Anatomical knowledge of variations in the glenoid fossa is a pre-requisite for successful management of shoulder surgery. Dimensions of glenoid fossa exhibit racial variations hence are important parameters for selecting appropriate shoulder implants. Scapular measurements can be used for comparative anatomy and manufacturing of prosthetic products. Further, this study may also be helpful for orthopedic surgeons during surgical interventions on the shoulder and for biomechanical engineers during designing of implants for reverse total shoulder replacement surgery.

REFERENCES

1. Gupta S. Morphometric analysis of glenoid fossa of scapulae. J Evol Med Dent Sci 2015;4:7761-6.
2. Preschler A, Klumpen T. The glenoid notch and its relation to the shape of the glenoid cavity of the scapulae. J Anat 1997;190:457-60.
3. Mamatha T. Morphometry of glenoid cavity. Online J Health Allied Sci 2011;10:7.
4. Cho BP, Kang HS. Articular facets of the coracoclavicular joint in Koreans. Acta Anat (Basel) 1998;163:56-62.
5. Mallon WJ. Radiographic and geometric anatomy of the scapulae. Clin Orthop Relat Res 1992;227:142-54.
6. Von Schroeder HP. Osseous anatomy of the scapulae. Clin Orthop Relat Res 2001;383:131-9.
7. Piyawinijwong S. The scapulae. Osseous dimensions and gender dimorphism in Thais. Siriraj Hosp Gaz 2004;56:358-65.
8. Burke RM. Can we estimate stature from the scapulae? A test considering sex and ancestry. Moscow, United States: BS University of Idaho; 2008.
9. Coskun N. Anatomical bases and variations of the scapulae in Turkish adults. Saudi Med J 2006;27:1320-5.
10. Krishnaiah M. Study of scapular measurements and scapular indices of Andhra Pradesh region. IOSR J Dent Med Sci 2014;13:117-20.

How to cite this article: Mahto AK, Omar S. Dimensions of Glenoid Fossa of Scapula: Implications in the Biomechanics of an Implant Design. Int J Sci Stud 2015;3(4):146-148.

Source of Support: Nil. **Conflict of Interest:** None declared.

|S|S JOURNAL

IJSS

International Journal of Scientific Study

www.ijss-sn.com

July 2015 - Volume 3 - Issue 4

INTERNATIONAL JOURNAL OF SCIENTIFIC STUDY

Abstracting & Indexing

- Index Medicus (IMSEAR)
- Global Index Medicus
- Index Copernicus
- Directory of Open Access Journals(DOAJ)
- Google Scholar
- WorldCat
- SafetyLit
- WHO Hinari
- Genamics Journal Seek
- Ulrichsweb Serials Solutions
- International Committee of Medical Journal Editors(ICJME)
- Geneva Foundation for Medical Education & Research(GFMER)
- Socolar
- Bielefeld Academic Search Engine(BASE)
- Research Bible
- Academic Journals Database
- J-Gate
- Jour Informatics
- NISCAIR
- Directory of Research Journal Indexing(DRJI)
- Scientific Indexing Services(SIS)
- Rubriq-Beta
- SHERPA RoMEO,
- New Jour
- E-International Journals of Academic & Scientific Research(EIJASR)
- IndianScience.in
- CiteFactor
- Scientific Journal Impact Factor (SJIF)
- Journal Index.net
- ROAD
- Global Impact Factor(GIF)
- International Society for Research Activity (ISRA)
- Advanced Science Index
- OpenAccessArticles.com

Original Article

DOI: 10.17354/ijss/2015/323

Clinico-anatomical Approach for Instrumentation of the Cervical Spine: A Morphometric Study on Typical Cervical Vertebrae

Ajay Kumar Mahto[1], Saif Omar[2]

[1]Professor, Department of Orthopedics, Katihar Medical College, Katihar, Bihar, India, [2]Associate Professor, Department of Anatomy, Katihar Medical College, Katihar, Bihar, India

Abstract

Introduction: Seven cervical vertebrae form the skeleton of the neck. These bones are the part of the axial skeleton. Four out of seven cervical vertebrae are typical on the basis of commonly prevailing characteristics. These centrally positioned and well-stacked bones support and position the head. The craniovertebral and intervertebral articulations provide the necessary flexibility.

Aim: The aim of the present study was to observe the morphology and morphometry of typical cervical vertebral body.

Materials and Methods: The present study was carried out on 240 adult dry human typical cervical vertebrae obtained from the Department of Anatomy of four medical colleges in Bihar to observe the dimensions of the vertebral bodies.

Result: Height of the vertebral bodies was observed to be larger at lower levels. Maximum anteroposterior length and transverse length were observed at C_6 and C_5, respectively.

Conclusion: Knowledge of both morphology and morphometry of typical cervical vertebrae is imperative for developing instrumentation related to the cervical spine. Ethnic variations have been reported in these dimensions.

Key words: Cervical vertebrae, Instrumentation, Morphology, Morphometry, Variations

INTRODUCTION

Cervical curvature plays an integral role in the proper functioning of the cervical spine. The summation of small movements occurring at the cervical intervertebral joints accounts for the high mobility and flexibility of the neck as an entity. The skeleton of the neck comprises seven small cervical vertebrae out of which four (C_3-C_6) are typical. Each vertebra consists of an anterior vertebral body and a posterior neural arch. The vertebral body has a central part of cancellous bone and a peripheral cortex of compact bone. The margins of upper and lower surfaces of the vertebral body are thickened to form vertebral rings. The neural arch is constituted by pedicles, laminae, spinous process, and articulating facets. The vertebral bodies are connected anteriorly by a long strong strap like anterior longitudinal ligament and a similar posterior longitudinal ligament. Fractures and dislocations of the spine are serious injuries as they may be associated with damage to the spinal cord or cauda equina. Instrumentation of the cervical spine is often used for the orthopedic management of pathologies resulting in cervical instability as well as for the decompression of neural structures. One of the most frequent and complex procedures for this is the placement of transpedicular screws.[1-4] The neural arches of adjacent vertebrae articulate with each other though facet joints which form synovial joints. Remaining portions of the neural arch of consecutive vertebrae are joined together by ligamentum flavum and other ligaments which are collectively termed as posterior ligament complex. Size of the vertebral bodies and both direction and size of the articular facets are different in different regions of the vertebral column. Previously morphometric studies of the cervical, thoracic, and lumbar vertebrae have been undertaken, and they have highlighted the importance of such studies in the development of vertebral

www.ijss-sn.com

Month of Submission 05-2015
Month of Peer Review 06-2015
Month of Acceptance 07-2015
Month of Publishing 07-2015

Corresponding Author: Dr. Saif Omar, Associate Professor, Department of Anatomy, Katihar Medical College, Katihar 854 185, Bihar, India. Phone No: +919431229989. E-mail: drsaifamar@gmail.com

column instrumentation.[3,8] Majority of these studies focus exclusively on the pedicle as this is the site where vertebral column fixation surgeries are most frequently implemented. Only a few studies describe the characteristics of the remaining elements that comprise the vertebra.[9,10] Most spinal surgeons agree to have adequate knowledge of spinal column morphology to avoid damage to the vertebral artery, spinal medulla, or nerve roots during fixation interventions involving posterior cervical spine.[11] Ethnic differences in dimensions of cervical spine have been reported across various populations. This study was taken up as no such citable previous study was performed in the state of Bihar.

MATERIALS AND METHODS

Two hundred and forty adult dry human typical cervical vertebrae were obtained from the Department of Anatomy of four medical colleges in Bihar to observe the dimensions of the vertebral bodies. Sex of the bone was not considered in the study. Only those vertebrae which were intact in all aspects were included in the study. Damaged, malformed, and vertebrae with signs of previous fractures were excluded from the study. All the measurements were conducted by using a sliding Vernier Calliper with 0.1 mm accuracy. Dimensions of the body were recorded in the following manner:

(a) Height: Distance between superior and inferior borders of the vertebral bodies at the midline
(b) Anterior-posterior length (APL): Distance between the anterior surface and posterior surface of the body at the midline
(c) Transverse length (TL): Distance between two lateral surfaces of the vertebral body (Figures 1-4).

Figure 1: Vertebrae C_3-C_6

Figure 2: Recording of anteroposterior length (mm)

RESULTS

Out of 240 cervical vertebral bodies studied, the maximum and minimum APL were observed at C_6 and C_3 respectively. TL was greatest at C_3 and smallest at C_7. The maximum body height was recorded at C_6 and lowest at C_1 (Tables 1 and 2).

DISCUSSION

Cervical spine instrumentation requires minute precision and thorough anatomical knowledge for a successful outcome. The management of spinal trauma either in isolation or a part of the polytraumatized patient is a difficult venture. Several authors have described the various parameters of the vertebral column in general by methods such as computed tomography scans and three-dimensional (3D) reconstructions. It has also been previously demonstrated that vertebral dimensional differences exist among different races,[7] and in this study, we have observed vertebral dimensions in Bihar region. The APD of a cervical vertebral body is an important parameter for the anterior fixation of bicortical screws.[8] In this study, we have observed that body height of typical cervical vertebra was minimum in C_1 and maximum in C_6. The APL was maximum and minimum at C_6 and C_3, respectively. The TL was greatest and least at C_3 and C_7, respectively. The exact dimensions of bodies of cervical vertebrae are an important tool in the planning of management and treatment of diseases related to the cervical spine. Knowledge of normal dimensions of vertebral bodies helps us to understand various clinical conditions such as stenosis and other space occupying



Figure 3: Recording of transverse length (mm)



Figure 4: Recording of height of vertebral body (mm)

lesions. Growth of the vertebral body may be related to genetic, racial, postural, and occupational factors. Body of cervical vertebrae from C_3-C_6 is somewhat box-shaped. Vertebral bodies appear to grow more in height than in depth and APL of a vertebral body is always greater than height. Variations in the components of the spine are so great that this subject has interested specialists from several fields. Spinal posture depends upon the anatomical and functional integrity of the vertebrae and if this integrity is lost clinical symptoms may develop.

CONCLUSION

Morphometry of vertebral bodies is useful for surgeons and orthopedicians who perform plate fixation during anterior cervical spine surgery. Variations in racial data must be taken into consideration during surgical procedures. Morphologic characteristics of the cervical vertebrae are responsible for the natural cervical lordosis curvature and the mobility of the cervical column. However prior to instrumentation,

Table 1: Comparison of the values of the typical cervical vertebrae observed in this study

Parameter	n	Maximum	Minimum
Height	240	C_4	C_6
APL	240	C_3	C_7
TL	240	C_3	C_7

C=Cervical vertebra, APL: Anterior-posterior length, TL: Transverse length

Table 2: Morphometric characteristics of the typical cervical vertebral bodies

Cervical vertebra	Mean±SD (mm)		
	APL	TL	Height
C_3 (n=60)	13.8±0.18	22.8±0.21	8.9±0.11
C_4 (n=60)	14.4±0.15	23.6±0.28	8.1±0.10
C_5 (n=60)	15.2±0.21	26.4±0.30	10.1±0.17
C_6 (n=60)	15.6±0.19	25.2±0.23	11.3±0.18

C=Cervical vertebra, APL: Anterior posterior length, TL: Transverse length, SD: Standard deviation

the orthopedic assessment of the spine should include evaluation of both skeletal and neurological injuries and a careful examination of both spinal and non-spinal injuries.

REFERENCES

1. Abuzayed B, Tanriverdi B, Kucukyuruk B, Tuzgen S. Anatomic basis of anterior and posterior instrumentation of the spine: Morphometric study. Surg Radiol Anat 2010;32:75-83.
2. Kayalioglu G, Erturk M, Varol T, Cezayirli E. Morphometry of the cervical vertebral pedicles as a guide for transpedicular screw fixation. Neurol Med Chir (Tokyo) 2007;47:102-7.
3. Sieradzki JP, Korankiewicz EE, Lautenschlager EP, Lazarus MI. Preoperative imaging of cervical pedicles: Comparison of accuracy of oblique radiographs versus axial CT scans. Eur Spine J 2009;17:1230-6.
4. Yusof MI, Ming LK, Abdullah MS. Computed tomographic measurement of cervical pedicles for transpedicular fixation in a Malay population. J Orthop Surg (Hong Kong) 2007;15:187-90.
5. Pal GP, Routal RV. The [illegible] of the vertebral foramina and the [illegible] of the cervical spine. J Anat 1996;188:485-9.
6. Pal GP, Routal RV. A study of weight transmission through the cervical and upper thoracic regions of the vertebral column in man. J Anat 1986;148:245-61.
7. Olsewski JM, Simmons EH, Kallen FC, Mendel FC, Severns CM, Berens DL. Morphometry of the lumbar spine: Anatomical perspectives related to transpedicular fixation. J Bone Joint Surg Am 1990;72:541-9.
8. Hou S, Hu R, Shi Y. Pedicle morphology of the lower thoracic and lumbar spine in a Chinese population. Spine (Phila Pa 1976) 1993;18:1655-5.
9. Rezaldua CJ. Morphometric study of cervical vertebrae C3-C6 in a population from northeastern Mexico. Int J Morphol 2011;29:325-30.
10. Winkelstein BA, McLendon RE, Barbir A, Myers BS. An anatomical investigation of the human cervical facet capsule, quantifying muscle insertion area. J Anat 2001;198:455-61.
11. Karaikovic EE, Kunakornsawat S, Ozuna MD, Madsen PW, Gaines RW Jr. Surgical anatomy of the cervical pedicles. Landmarks for posterior cervical pedicle entrance localization. J Spinal Disord 2000;13:63-72.
12. Arriola-Vega E. Morphometry of pedicle and vertebral body in a Mexican population by CT and fluoroscopy. Int J Morphol 2009;27:1299-303.

How to cite this article: Mahto AK, Omar S. Clinico-Anatomical Approach for Instrumentation of the Cervical Spine: A Morphometric Study on Typical Cervical Vertebrae. Int J Sci Stud 2015;3(4):143-145.

Source of Support: Nil, **Conflict of Interest:** None declared.

ISS JOURNAL

IJSS

International Journal of Scientific Study

www.ijss-sn.com

August 2015 - Volume 3 - Issue 5

INTERNATIONAL JOURNAL OF SCIENTIFIC STUDY

Abstracting & Indexing

1. Index Medicus (IMSEAR)
2. Global Index Medicus
3. Index Copernicus
4. Directory of Open Access Journals(DDAJ)
5. Google Scholar
6. WorldCat
7. SafetyLit
8. WHO Hinari
9. Genamics Journal Seek
10. Ulrichsweb Serials Solutions
11. International Committee of Medical Journal Editors(ICJME)
12. Geneva Foundation for Medical Education & Research(GFMER)
13. Socolar
14. Bielefeld Academic Search Engine(BASE)
15. Research Bible
16. Academic Journals Database
17. J-Gate
18. Jour Informatics
19. NISCAIR
20. Directory of Research Journal Indexing(DRJI)
21. Scientific Indexing Services(SIS)
22. Rubriq-Beta
23. SHERPA RoMEO,
24. New Jour
25. E-International Journals of Academic & Scientific Research(EIJASR)
26. IndianScience.in
27. CiteFactor
28. Scientific Journal Impact Factor (SJIF)
29. Journal Index.net
30. ROAD
31. Global Impact Factor(GIF)
32. International Society for Research Activity (ISRA)
33. Advanced Science Index
34. OpenAccessArticles.com

Original Article

DOI: [illegible]

Carpal Tunnel Syndrome: Prevalence and Association with Occupation among Presenting Cases in a Tertiary Care Hospital in North East Bihar

Ajay Kumar Mahto[1], Saif Omar[2]

[1]Professor, Department of Orthopaedics, Katihar Medical College, Katihar, Bihar, India. [2]Associate Professor, Department of Anatomy, Katihar Medical College, Katihar, Bihar, India

Abstract

Background: Carpal tunnel syndrome (CTS) is a disorder that causes pain and weakness in the hand and wrist. It usually develops from compression of median nerve when it passes deep to the flexor retinaculum through the carpal tunnel in the wrist. It is characterized by the presence of both sensory and motor presenting features in the peripheral distribution of the nerve. A number of etiological factors have been suggested for the onset of CTS including repetitive prolonged hand activities, recurrent exposure to vibration, extremes of temperatures and mechanical stress. Evolution of the pathophysiology of CTS is not clearly understood, but it appears that the median nerve is compressed when the tissues of the hand surrounding the nerve swell in response to trauma or inflammation. It is often very difficult to determine the precise cause of onset of CTS. Older people are at a higher risk due to degenerative neuropathy.

Aim: The aim of this study was to observe the prevalence of CTS and its association with the occupation.

Materials and Methods: Patients attending the outdoor clinics of Katihar Medical College and presenting with complaints of tingling, burning, numbness, and pain in the hands were referred to the Department of Orthopedics for further clinical examination, diagnosis and management. Cases were categorized into two groups. The first group comprised persons engaged in heavy manual work and the second group consisted of persons engaged in light manual work.

Result: Prevalence of CTS was higher in the first group as CTS is usually triggered in cases with occupation consisting of prolonged heavy manual work.

Conclusion: CTS has a direct relation with occupation and some medical conditions may increase the susceptibility towards developing CTS. Early diagnosis, rest and conservative approach are preferred for the management of CTS.

Key words: Carpal tunnel syndrome, Compression, Median nerve, Occupation

INTRODUCTION

The flexor retinaculum is a strong fibrous band which acts as a tie-beam and converts the anterior concave surface of the carpus into an osseo-fibrous carpal tunnel. Through this tunnel pass the digital flexor tendons and the median nerve. The median nerve is the chief nerve of sensation in the hand as it supplies the palmar surfaces of the digits the most common employed for feeling and for precision grip. In addition, it is motor to the thenar eminence musculature. The median nerve enters the hand by passing deep to the flexor retinaculum. The median nerve may be compressed in the carpal tunnel due to continued swelling of the synovial sheaths. This is known as the carpal tunnel syndrome (CTS) and is manifested by weakness and wasting of thenar muscles with the loss of power of opposition, and loss

Article this article online

IJSS

www.ijss-sn.com

Month of Submission : 07-2015
Month of Peer Review : 07-2015
Month of Acceptance : 07-2015
Month of Publishing : 08-2015

Corresponding Author: Dr. Saif Omar, Department of Anatomy, Katihar Medical College, Katihar 854 105, Bihar, India.
Phone: +91-9431229999. E-mail: drsaifomar@gmail.com

of cutaneous sensations of the palmar surface involving lateral three and a half of the digits.[1] Upon emerging from the carpal tunnel, the median nerve ramifies. A muscular branch innervates the thenar muscles. Remaining branches terminate in the palmar digital nerves for the thumb, index middle, and ring fingers. A communicating branch usually links the nerve to the ulnar nerve. The median nerve is prone to compression in the carpal tunnel.[2] The CTS provides an instructive demonstration of the distribution of the median nerve. Only by knowing its anatomy, it is possible to distinguish this condition from other syndromes that cause paresthesias and muscle atrophy in the hand. The condition is more common in women and often there is no identifiable cause. The syndrome may be precipitated by arthritis of the wrist or intercarpal joints, dislocation of the lunate, tenosynovitis, tumor or acromegaly. Irritation of the nerve may cause a tingling sensation and twitching of the thenar muscles. Due to nerve paralysis, the thenar muscles atrophy and there is anesthesia in the sensory distribution area of the nerve. Movements of fingers and thumb are not seriously impaired. Division of the flexor retinaculum at the wrist relieves symptoms and signs of the compression syndrome. In long-standing cases, nerve regeneration may not take place.[3] CTS is a common problem with an estimated annual incidence rate of 0.5-5.1 per 1000.[4] Certain occupations, involving wrist activities materially increase the risk of CTS. This syndrome can also produce nocturnal symptoms including hand or arm pain and numbness. CTS was first reported 1947 by brian among six cases of CTS in repetitive work.[5] It is the most common compressive neuropathy of the upper limb and an increasingly recognized cause of work disability.[6] CTS belongs to a ménage of disorders called cumulative trauma disorders (CTDs) which are caused by the repetitive, sustained, or forceful motions occurring over time, compromising the integrity or functioning of the soft tissues producing inflammation of the tendons or compression of the peripheral nerves. Higher prevalence rates have been observed in certain groups with repetitive hand movements especially flexion at the wrist joint and extension at the shoulder and elbow joints. Diagnosis of CTS is based on characteristic complaint confirmed preferably by abnormal electrophysiological tests.[8] In the United States, occupational CTS is a major cause of loss of working days for workers and carpal tunnel release is the most common preferred operation on the hand, accounting for approximately two hundred, thousand procedures each year incurring direct medical costs in excess of one billion dollars annually. More rigorous study of treatment for CTS will be enhanced by better measures of outcome. CTS is reported to be more common in women. No tests are yet available to target the causative factor.

MATERIALS AND METHODS

A cross-sectional study which evaluated the prevalence of CTS and its association with occupation among the general population was undertaken in a tertiary care center in North East Bihar. Ethical committee clearance was obtained prior to the study. 80 cases of CTS which attended the outdoor Orthopedic Clinic of Katihar Medical College were observed in this study. Cases were categorized into two Groups A and B. Group A consisted of cases engaged in heavy manual work and Group B consisted of cases engaged in light manual work.

Inclusion Criteria

1. Adult males
2. Adult females
3. Cases with intact surgical anatomy of wrist and joint
4. Cases with no past history of nerve injury or pre-existing diseases.

Exclusion Criteria

1. Geriatric males
2. Geriatric females
3. Cases presenting with fracture repair of distal radius, distal ulna or any of the carpus
4. Cases presenting with hormonal conditions and arthritis.

RESULTS

All 80 cases were adults and no pediatric case of CTS was observed. There were 60 cases in Group A of which all were persons involved in occupations concerned with heavy manual work. Twenty cases observed in Group B were involved in occupations concerned with light manual work. In Group A out of 60 presenting cases the occupations of the cases are as follows: drill machine operators (22), construction laborers (16), drivers (12), automotive garage mechanics (5), butchers (3), and railway station porters (2). In Group B out of 20 presenting cases the occupations of the cases are as follows; chefs (6), computer operators (4), tailors (3), gardeners (3), office clerks (2), billboard painters (2). Out of 80 presenting cases, irrespective of group the prevalence among males and females were 53 out of 80 (66.25 %) and 27 out of 80 (33.75 %) respectively (Table 1-4).

DISCUSSION

CTS is considered an inflammatory disorder caused by repetitive stress, physical injury or a medical condition. CTS is the most common chronic entity seen by the

health surgeons with some reporting that the condition affects up to 10% of the general population.[11] It is often very difficult to determine the precise cause. The most important problem associated with this occupational exposure is the complexity of exposure assessment at the workplace. No tests are yet available to target the causative factor. Except in patients with certain underlying diseases, the biological mechanisms leading to CTS are unknown. Some studies suggest that more than half of CTS cases are associated with workplace factors, though there is no strong evidence of cause and effect relationship. CTS is felt to be induced or aggravated by any process that compresses the median nerve as it passes through the narrow carpal canal. Repetitive flexion and extension of the wrist and grasping motions of the hand are thought to repeatedly compress the median nerve between the tendons and carpal bones, leading to nerve injury. Such recurring movements at the wrist joint also make a person prone to develop tendonitis and tenosynovitis. Repetitive heavy manual work or light manual work both can trigger CTS. In this study, we observed 80 cases of CTS which were associated with occupation (Table 1). Prevalence of CTS in relation with occupation and among different genders has been illustrated in Figures 1 and 2. Distribution of cases of CTS among heavy and light workers has been represented in Figures 3 and 4. Heavy manual workers are more prone to developing onset of CTS. As pregnancy was an exclusion criteria in this study we observed that males were more vulnerable to CTS (Table 2). With relation to the occupation in Group A, we observed drill machine workers are more susceptible to CTS due to prolonged use of heavy vibration tools (Table 3). Prolonged vibration exposure resulting in CTS has been documented by Leclerc *et al.*[12] In Group B, we observed that chefs are more vulnerable to CTS due to repetitive and prolonged use of the wrist joint in all stages of cooking, being seconded by professional computer operators (Table 4). Studies now strongly suggest that CTS is primarily associated with medical conditions such as diabetes mellitus, osteoarthritis, hypothyroidism and rheumatoid arthritis. Prevalence of CTS in the general population ranges from 1% to 25% which is comparatively very low.[13] This syndrome also tends to occur in people with certain genetic or risk factors including obesity, smoking and alcohol abuse. In pregnant women, hormonal fluctuations may trigger CTS due to fluid retention. CTS is typically worse at night and with repetitive activity.[14] Pain or muscle weakness may prevent a person a person from doing important day-to-day tasks and also affect a person's hobbies. Individuals with CTS are unable to oppose the thumb and have difficulty buttoning a shirt or blouse as well as gripping things such as a comb. As the condition progresses sensory changes radiate to the forearm and axilla.[15] Workers may be compelled to opt for another occupation. It is advisable to begin early conservative treatment to avoid surgical intervention. The most common type of conservative treatment is corticosteroid injections

Table 1: Number of cases in each group

Number of presenting cases	Group A	Group B
n=80	60	20

Prevalence among cases in Group A is more than that of Group B

Table 2: Prevalence of CTS among males and females observed in this study

Number of presenting cases	Prevalence among males (%)	Prevalence among females (%)
n=80	53 (66.25)	27 (33.75)

Group has not been considered in this table. CTS: Carpal tunnel syndrome

Table 3: Occupation specific distribution of cases in Group A

Group A (*n*=60)	Occupation
22 cases	Drill machine operators
16 cases	Construction labourers
12 cases	Drivers
5 cases	Automotive garage workers
3 cases	Butchers
2 cases	Railway station porters

Table 4: Occupation specific distribution of cases in Group B

Group B (*n*=20)	Occupation
6 cases	Chefs
4 cases	Computer operators
3 cases	Tailors
3 cases	Gardeners
2 cases	Office clerks
2 cases	Billboard painters

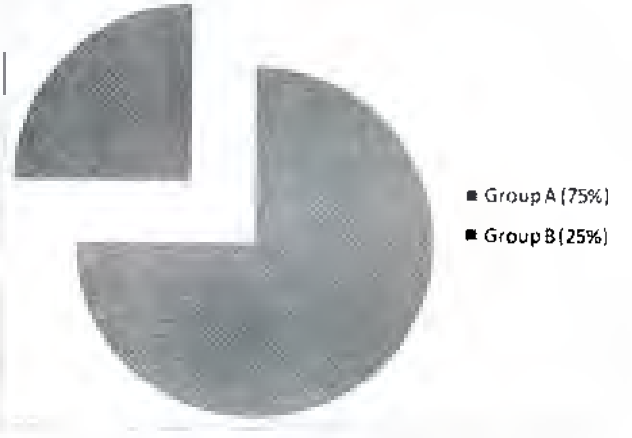

Figure 1: Prevalence of carpal tunnel syndrome in relation with nature of occupation. Group A contains 60/80 (75%) cases and Group B 20/80 (25%) cases observed in this study



Figure 2: Prevalence of carpal tunnel syndrome (CTS) among males and females. Group to which the male or female belongs has not been considered in this figure. Result shows that prevalence of CTS among males is higher than that among women

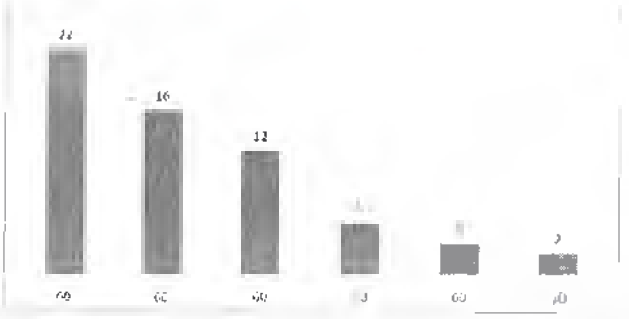

Figure 3: Distribution of cases presenting with carpal tunnel syndrome in Group A

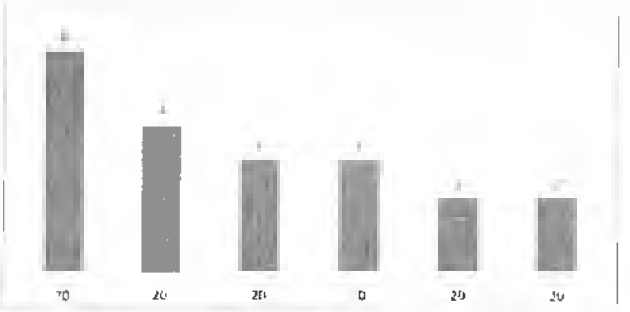

Figure 4: Distribution of cases presenting with carpal tunnel syndrome in Group B

that are quite successful in mild cases of CTS. In all the cases we encountered, rest and physiotherapy was advised with considerable results. In a follow up, we observed that the inflammation of adjacent tissues had subsided, and compression symptoms of the median nerve were substantially relieved.

CONCLUSION

Anatomical knowledge of the carpal canal and clinical knowledge of CTS are both crucial for assessing the prognosis of median nerve entrapment neuropathy. CTS exhibits female predilection due to smaller wrists and lower carpal tunnel volumes. Heavy manual workers using heavy duty vibration tools are vulnerable to CTS. Experts have suggested that people who are physically fit have a lower risk for developing CTS. Regular regimen involving resistance training strengthens the muscles of the girdles and the limbs.

REFERENCES

1. Datta AK. Essentials of Human Anatomy Superior and Inferior Extremities. 3rd ed. Reprint. Kolkata: Current Books International, 2007. p. 86.
2. Rosse C. Hollinshead's Textbook of Anatomy. 5th ed. Philadelphia: Lippincott-Raven, 1997. p. 286.
3. Rosse C. Hollinshead's Textbook of Anatomy. 5th ed. Philadelphia: Lippincott-Raven, 1997. p. 287.
4. Jagga V. Occupation and its association with carpal tunnel syndrome: A review. J Exercise Sci Physiother 2011;7:68-78.
5. Brian RW. Spontaneous compression of both median nerves in the carpal tunnel syndrome. Lancet 1947;1:277-82.
6. Pai MB. Symptoms of carpal tunnel syndrome in a dental work force in a developing country. Int J Adv Res 2014;2:87-94.
7. Silverstein BA, Fine LJ, Armstrong TJ. Hand wrist cumulative trauma disorders in industry. Br J Ind Med 1986;43:779-84.
8. de Krom MC, Knipschild PG, Kester AD, Thijs CT, Boekkooi PF, Spaans F. Carpal tunnel syndrome: Prevalence in the general population. J Clin Epidemiol 1992;45:373-6.
9. Levine DW, Simmons BP, Koris MJ, Daltroy LH, Hohl GG, Fossel AH, *et al*. A self-administered questionnaire for the assessment of severity of symptoms and functional status in carpal tunnel syndrome. J Bone Joint Surg Am 1993;75:1585-92.
10. Atroshi I, Gummesson C, Johnsson R, Ornstein E, Ranstam J, Rosen I. Prevalence of carpal tunnel syndrome in a general population. JAMA 1999;282:153-8.
11. Weinstein SL. The wrist and hand. Turek's Orthopaedics Principles and their Application. 6th ed. Ch. 14. Philadelphia: Lippincott Williams & Wilkins, 2005. p. 418.
12. Leclerc A, Landre MF, Chastang JF, Niedhammer I, Roquelaure Y. Study Group on Repetitive Work. Upper-limb disorders in repetitive work. Scand J Work Environ Health 2001;27:268-78.
13. Morse TF, Michalak-Turcotte C, Atwood-Sanders M, Warren N, Peterson DR, Bruneau H, *et al*. A pilot study of hand and arm musculoskeletal disorders in dental hygiene students. J Dent Hyg 2003;77:103-9.
14. Hamann C, Werner RA, Franzblau A, Rudgers DA, Siew C, Gruninger S. Prevalence of carpal tunnel syndrome and median mononeuropathy among dentists. J Am Dent Assoc 2001;132:163-70.
15. Moore KL. Upper limb. Clinically Oriented Anatomy. 5th ed. Ch. 6. Philadelphia: Lippincott Williams & Wilkins, 2006. p. 843.

How to cite this article: Mahto AK, Omar S. Carpal Tunnel Syndrome: Prevalence and Association with Occupation among Presenting Cases in a Tertiary Care Hospital in North East Bihar. Int J Sci Stud 2015;3(5):108-111.

Source of Support: Nil. **Conflict of Interest:** None declared.

ISS JOURNAL

IJSS

International Journal of Scientific Study

www.ijss-sn.com

August 2015 - Volume 3 - Issue 5

Original Article

DOI: 10.17354/ijss/2015/355

Enthesophytes and Tubercles of the Calcaneum: An Anatomical and Clinical Understanding of the Relationship between Calcaneal Spurs and Plantar Heel Pain

Ajay Kumar Mahto[1], Saif Omar[2]

[1]Professor, Department of Orthopaedics, Katihar Medical College, Katihar, Bihar, India, [2]Associate Professor, Department of Anatomy, Katihar Medical College, Katihar, Bihar, India

Abstract

Background: Calcaneus is the largest of all the bones that constitute the skeleton of the foot. It is also the largest tarsal bone and plays a pivotal role in weight transmission, weight bearing, gait, and posture. In professions involving long durations of standing and in disorders such as obesity there may be growth of abnormal bone tissue at the site of tendinous attachments known as enthesophytes or spurs. Radiologically these spurs may differ from the naked eye and clinical examinations. The apices of these spurs are often embedded in the plantar fascia of the foot.

Aim: The aim of the present study was to observe the enthesophytes and tubercles of dry adult human calcanei.

Materials and Methods: One hundred dry adult human intact calcanei were obtained from the four different medical colleges in the state of Bihar and observed in detail. Bones were of unknown, age and sex and were supposedly from cadavers of Bihar origin.

Results: Tha incidence of calcaneal spurs was reported to be 22% with laterality of 14 and 8 in right and left sides, respectively. Our findings have been compared with those of other researchers. Medial tubercle was larger than lateral tubercle, and all enthesophytes were observed to be originating from the medial tubercle only.

Conclusion: Calcaneal enthesophytes or spurs may be related to the nature of work or orthopedic pathology. Probable other factors that may increase the incidence of spur formation are uncontrolled weight gain, advancing age, and constant use of uncomfortable footwear.

Key words: Calcaneus, Enthesophytes, Pain, Spurs, Tubercles

INTRODUCTION

The foot extends from the point of the heel to the roots of the toes. Superior and inferior surfaces of the foot are referred to as dorsum and plantar, respectively. The foot is divided into tarsus and metatarsus. The tarsus is the posterior half formed by the tarsal bones, which are arranged in two rows. The proximal row consists of talus and calcaneus, whereas the distal row consists of cuboid, navicular, and cuneiform. The largest of the tarsals, the calcaneus forms an irregular block of bone. It is also referred to as heel bone and forms a major component of the skeleton of the hindfoot and prominence of the heel.[1] The calcaneus is the longest, strongest, and largest of all the tarsal bones. It is the first bone in the foot to ossify and is also the most frequently injured tarsal bone. It transmits the weight of the body to the ground. This bone also provides leverage for the action of the posterior calf muscles attached to its broader and non-articular posterior surface. Very rarely, the calcaneum may also present itself with a set of accessory bones.[2] Being irregularly cuboidal in shape,

www.ijss-sn.com

Month of Submission : 06-2015
Month of Peer Review : 07-2015
Month of Acceptance : 07-2015
Month of Publishing : 08-2015

Corresponding Author: Dr. Saif Omar, Department of Anatomy, Katihar Medical College, Katihar 854 105, Bihar, India.
Phone: +91-9431229999 E-mail: drsaifomar@gmail.com

it presents six surfaces and a shelf-like bony projection the sustentaculum tali which as the name implies sustains the head of the talus and also bears the greatest weight per area. The calcaneus bears four tubercles, anterior, lateral, and medial which are pcesent on the inferior or plantar surface and a small peroneal tobercle on the lateral surface. Occasionally, an enthesophyte has been observed growing anteriorly along the calcaneal tuberosity along the entire width of the bone. Plantar fasciitis is the most common cause of plantar heel pain. Clinically, the etiology and pathophysiology of enthesophyte formation in calcaneum has not yet been clearly understood. In spite of different treatment modalities of a heel spur, the association of incidence of calcaneal spur with clinical and functional parameters in nonconclusive. It has been suggested that longitudinal traction or vertical compression may be the causative factors. Enthesophyte formation usually occurs at the site of ligamentous and tendinous insertions into the bone. An enthesophyte tends to grow in the direction of natural pull of ligaments and tendons involved.[7] The lateral and medial tubercles of calcaneus provide sites for the origin of muscles of the various layers of the sole. The medial tubercle gives origin to abductor hallucis, flexor digitorum brevis, and abductor digiti minimi. The lateral tubercle gives origin to abductor digiti minimi and lateral head of flexor digitorum accessorius. The anterior tubercle provides attachment to the short plantar ligament, and the long plantar ligament is attached to the rough strip between the three tubercles. The peroneal tubercle lies between the tendons of peroneus brevis above and peroneus longus below. Variations in the gross morphology of the calcaneus have been reported in the literature with reference to sex, race, and occupation; but there are few citable references regarding the observation on tubercles and incidence of calcaneal enthesophytes. The most enthesophytes are encountered radiographically or clinically during surgical procedures, but our study focuses on observing the incidence of enthesophytes in dry bone by naked eye examination.

MATERIALS AND METHODS

One hundred dry intact adult human calcanei were observed in details for enthesophytes. The bones were supposedly of Bihar origin. Sex of the bone was not taken into consideration. Specimens that showed signs of damage or previous fracture were discarded from the study. Naked eye examination of all the bones was performed, and incidence of spurs was recorded. Handheld magnifying lens was used for observing the peroneal tubercle (Figures 1-4).

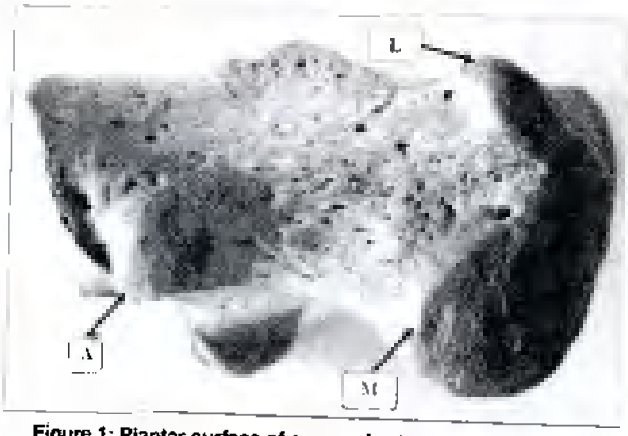

Figure 1: Plantar surface of a normal calcaneus showing the normal morphology of three tubercles (A) anterior (M) medial (L) lateral. The medial tubercle is larger than all other tubercles. Concavity present between the three tubercles in a normal calcaneus is smooth. Peroneal tubercle is not shown in this figure

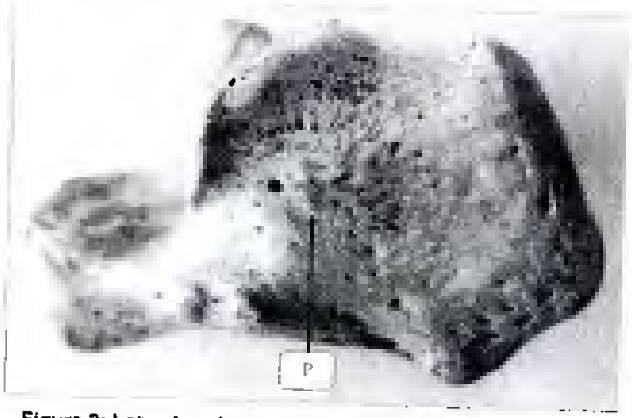

Figure 2: Lateral surface of a normal calcaneus showing the normal morphology of the peroneal tubercle (P). Concavities present both above and below the tubercle are for the tendons of peroneus brevis and peroneus longus, respectively

Figure 3: Specimen of calcaneus showing small enthesophytes arising from both lateral and medial tubercles. E_M and E_L denote the enthesophytes arising from the medial and lateral tubercles, respectively

Inclusion Criteria

- Bones belonging to cadavers of Bihar origin
- Bones with intact gross morphology and tubercles
- Bones belonging to adult
- Bone which were available in pairs.

Exclusion Criteria

- Bones which were unpaired
- Bones with abnormal morphology and tubercles
- Bones belonging to children
- Bones which showed signs of previous fracture.

Observation

Of 100 calcanei observed ($n = 100$) enthesophytes were observed in 22 specimens. All the specimens studied presented with four tubercles. Medial tubercles were larger in all specimens. The total incidence in this study was 22% out of which fourteen were on the right side, and eight were on the left side, respectively (Tables 1-4).

Figure 5 shows the incidence of enthesophytes in the present study.

Figure 6 shows a pictorial representation of laterality of incidence of enthesophytes in the present study. On the right side, enthesophytes were observed in 14 out of 22 calcanei. On the left side, enthesophytes were observed in 8 out of 22 calcanei.

Table 1: Incidence of enthesophytes in this study

Total number of calcanei observed	Incidence of enthesophytes
n=100	22%

Table 2: Number of tubercles in each calcaneus observed

Total number of calcanei observed	Tubercles present in each calcaneus
n=100	A/P/L/M

A: Anterior, P: Peroneal, L: Lateral, M: Medial

Table 3: Largest of all the tubercles in each calcaneus observed

Total number of calcanei observed	Largest tubercle
n=100	Medial tubercle

Table 4: Incidence of laterality of enthesophytes in this study

Incidence of enthesophytes	Laterality of incidence
22%	R=14/22 (64%) and L=08/22 (36%)

DISCUSSION

Enthesophytes were observed in 22 out of 100 bones examined in this study. In this study, we observed that there was no spur formation from either of the anterior, lateral, and peroneal tubercles of any specimen. Only in three specimens, we observed enthesophytes originating



Figure 4: Specimen of calcaneus showing an enthesophyte arising from the concavity of the plantar surface of the anterior, medial, and lateral tubercles. Location of the enthesophyte is indicated in figure by an arrow (E)



Figure 5: Incidence of enthesophytes. Enthesophytes were observed in 22 out of 100 calcanei studied with an incidence of 22%

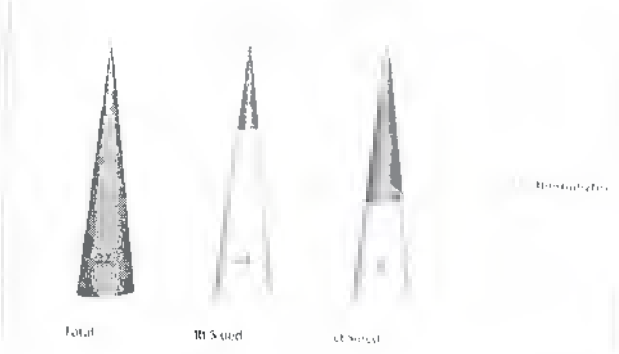

Figure 6: Pictorial representetion of laterality of incidence of enthesophytes

Table 5: Comparison of incidence of calcaneal enthesophytes in different studies

Researcher	Year	Sample size (*n*)	Incidence (%)
Resnick[14]	1977	Not available	22
Prichasuk and Subhadrabandhu[15]	1994	Not available	15.5
Riepert[16]	1995	Not available	15.7
Menz *et al.*	2008	216	55.1
Perumal	2013	218	56
Kullar *et al*	2013	200	26.5
Omar	2015	100	22

from both medial and lateral tubercles. These findings have been pictorially represented in Figures 1 and 2. Such enthesophytes may occur on the plantar surface of the bone due to deposition of calcium salts and on the fibrous tissue attached to the tubercles. Many such related studies have highlighted this occurrence of enthesophyte formation based on radiological data of the western population. The formation of spurs was due to compression force exerted on the bone due to weight bearing.[8] Irrespective of their origin calcaneal spurs result in heel pain and interfere with daily activities. Calcaneal spurs have also been reported in young individuals.[9] Intra-articular incongruity, varus and valgus misalignment of the heel, widened heel due to lateral bulge, shorter heel height, decreased ankle dorsiflexion, and elevated Achilles tendon insertion leading to weakening of the gastrocnemius-soleus complex can result in enthesophyte formation in the calcaneus. The attachment of the plantar fascia to the calcaneus may become ossified, or a similar spur may occur related to the insertion of the tendo Achilles. Spurs are usually seen in the middle age or later and are usually asymptomatic.[10] All enthesophytes observed had a hook or semi-hook like appearance from the lateral aspect. It could be due to an increased axial load or obesity.[11] Calcaneal enthesophytes appear to be multifactorial in origin and in our study it is evident that all enthesophytes are extending from the medial tubercle. A detailed analysis of patterns of anterior talar articular facets in a series of 401 Indian calcanei revealed four types. Type I (67%) showed one continuous facet on the sustentaculum extending to the distomedial calcaneal corner; Type II (26%) presented two facets, one sustentacular and one distal calcaneal; Type III (5%) only a single sustentacular facet; and Type IV (2%) showed confluent anterior and posterior facets.[12] In this study, the incidence of calcaneal enthesophytes was lower than Menz *et al.*,[13] Anand[8] and Kullar *et al.* gender may be a cofactor leading to heel pain. We have compared to our findings with those of previous researchers in Table 5. A higher frequency of calcaneal spur formation in individuals with abductor digiti minimi has also been reported.[3] As sex and age of the bones were not considered it was not possible to comment on the gender and age group having higher or lower incidence of calcaneal enthesophytes. A further study with these parameters may be performed in the future. Our findings shall serve as a guide for podiatrists with who deal with calcaneal enthesophytes.

CONCLUSION

Calcaneal enthesophytes are bony outgrowths of the calcaneus that are common findings on radiographic examinations of the foot and ankle. Such outgrowths can extend on the whole extent of the calcaneus. Anatomical knowledge of calcaneal enthesophytes is clinically relevant as these spurs affect the normal alignment of the calcaneus. Misalignments lead to instability and are a frequent cause of heel pain. Enthesophyte formation usually occurs in the medial tubercle of calcaneum and is probably due to biomechanical reasons. The factors that aggravate the incidence of spurs are increasing weight, obesity, advancing age, and concurrent orthopedic diseases. Ethnic and developmental variations must also be considered. Theoretically, calcaneal enthesophytes may be an adaptive response to vertical compression of the heel. Regular wearing of uncomfortable or improper footwear can also be a causative factor.

REFERENCES

1. Rosse C. Hollinshead's Textbook of Anatomy. 5th ed. Philadelphia: Lippincott-Raven. 1997. p. 343.
2. Kullar JS, Randhawa GK, Kullar KK. A study of calcaneal enthesophytes (spurs) in Indian population. Int J Appl Basic Med Res 2014;4:513-6.
3. Snell RS. Bones of the foot. Clinical Anatomy for Medical Students. 6th ed. Philadelphia: Lippincott Williams & Wilkins. 1993. p. 551-2.
4. Chakrabarty N. Fundamentals of Human Anatomy. Kolkata: New Central Book Agency. 1994. p. 309.
5. Chundru U, Fichesklnd A, Seidelmann F, Fogel J, Franklin P, Beltran J. Plantar fasciitis and calcaneal spur formation are associated with abductor digiti minimi atrophy on MRI of the foot. Skeletal Radiol 2008;37:505-10.
6. Perumal A. Morphometric study of spur formation in dry adult human calcaneae. Int J Curr Res Rev 2013;5:92-6.
7. Rogers J, Shepstone L, Dieppe P. Bone formers: Osteophyte and enthesophyte formation are positively associated. Ann Rheum Dis 1997;56:85-90.
8. Anand A. Morphometric study of spur formation in dry adult human calcaneae. Int J Curr Res Rev 2013;5:92-6.
9. Reeves B. Development of an OS calcaneal spur in a boy between the ages of 10 and 14 years. Ann Rheum Dis 1965;24:66-7.
10. Decker GA, Lee McGregor's Synopsis of Surgical Anatomy. 12th ed. Bombay: Wright-Varghese. 1986. p. 546.
11. Jakob C. Association of calcaneal spurs with above average body weight. Texas A&M Health Science Center College of Medicine. Temple, TX.
12. Standring S. Gray's Anatomy. The Anatomical Basis of Clinical Practice. 40th ed. Spain: Churchill Livingstone Elsevier. 2008. p. 1437.
13. Menz HB, Zammit GV, Landorf KB, Munteanu SE. Plantar calcaneal spurs in older people: Longitudinal traction or vertical compression? J Foot Ankle Res 2008;1:7.
14. Resnick D. Calcaneal abnormalities in articular disorders. Radiology 1977;125:355-66.

15 Prichasuk S, Subhadrabandhu T. The relationship of pes planus and calcaneal spur to plantar heel pain. Clin Orthop Relat Res 1994 192-6

16 Riepert T, Drechsler T, Schild H, Nafe B, Mattern R. Estimation of sex on the basis of radiographs of the calcaneus. Forensic Sci Int 1996;77:133-40

How to cite this article: Mahto AK, Omar S. Enthesophytes and Tubercles of the Calcaneum: An Anatomical and Clinical Understanding of the Relationship between Calcaneal Spurs and Plantar Heel Pain. Int J Sci Stud 2015;3(5):99-103.

Source of Support: Nil. **Conflict of Interest:** None declared.

International Journal of Advances in Health Sciences (IJHS)

search...

ISSN 2349-7033

Home

IJHS -**Call of Papers For Volume2 Issue5**

We would like to inform you that international open access, peer reviewed bimonthly journal "**International Journal of advances in health sciences (IJHS)**" is going to publish its latest issue (Volume 2 Issue 5) in the month of Sept 2015.

International Journal of advances in health sciences (IJHS) is officially nonprofit open access peer reviewed double blind international journal covers research/reviews in all areas of medical sciences from basic to advances in health, dental and pharmaceutical sciences with experimental and clinical practices. IJHS is published Bi-Monthly with 06 issues per year.

Frequency: Bi-Monthly (Print+Online)
Language: English
Impact Factor: 1.47
Abbreviation: Int. J Adv Health Sci.
CODEN: IJAHS
Category: Health and Allied Scieces
License: Creative commons

IJHS - Author Benefits specific Authors:

- Easy & Rapid paper publishing process.
- **IJHS provides one color Hard copy of full Paper with journal full cover.**
- **IJHS provides Hard & Soft Copy of Certificate of Publication to each Author.**
- **IJHS** is indexed in DOAJ, **INDEX Copernicus**, DRJI, SCIRUS, Google Scholar, getCITED etc.
- International Open Access Journal Database for High visibility and promotion of your articles.

Health Sciences, Dental Sciences, Pharmacology, Anatomy, Physiology, Biochemistry, Medicine, Neurology, Surgery, Orthopaedics, Ophthalmology, ENT, Anesthesiology, Community Medicine, Public Health, Physiotherapy, Rehabilitation, Occupational Therapy, Paramedical sciences, Nursing, Health and Hospital Management, Genetics, Biodiversity & Conservation, Pathology, Microbiology, Biotechnology, Occupational and Environmental sciences, Molecular Biology, Clinical Psychology, Psychiatry, Psychotherapy, Dietetics & Nutrition, Yoga etc.

Submission of The manuscripts to IJHS may include innovative experimental techniques of health importance; novel results obtained experimentally, novel interpretation of existing results or data pertaining to clinical problems; epidemiological work for scientific information which benefits to health sciences.

Editor-in-Chief (IJHS)

International Journal of Advances in Health Sciences (IJHS)
ISSN 2349-7033
Vol2, Issue2, 2015, pp171-174
http://www.ijhsonline.com

Research Article

Morphometry of the scaphoid waist: A better understanding for hand surgery

Masroor Alam[1], Saif Omar[2], Nafees Fatima[3] and Khurshid Alam[4]

Department of Orthopaedics, Katihar Medical College, Katihar, Bihar, India[1]
Department of Anatomy, Katihar Medical College, Katihar, Bihar, India[2]
Department of Anatomy, IGIMS, Patna, Bihar, India[3]
Department of Anatomy, Patna Medical College, Patna, Bihar[4]
Corresponding Author – Email: drsaifomar@gmail.com, (M) +919431229999

[Received-14/03/2015, Accepted-21/03/2015]

ABSTRACT

The scaphoid bone is one of the eight small bones of the carpus. Along with the lunate and the distal carpal articular surface of the radius, it forms the wrist joint, an ellipsoid variety of synovial joint. The eight small bones arranged in two rows act together to allow simple translational movement and thereby play a special role in wrist stability and in coordinating various movements at the wrist joint. The scaphoid hone is vulnerable to fracture because of its position within the wrist. It is the most frequently fractured carpal bone accounting for seventy-one percent of all carpal hone fractures. This study was performed to observe the circumference of the scaphoid waist. Our study was focused on dry adult scaphoid specimens of humans in population of Bihar and our findings can be useful for clinicians.

Keywords – Scaphoid, Waist, Fracture, Foramina

INTRODUCTION

The scaphoid bone is the largest bone in the proximal row of carpal bones. The word scaphoid is derived from the Greek word "*skaphe*" for boat. The scaphoid is an obliquely oriented bone on the radial side of the wrist, which articulates with the radius, lunate, capitate, trapezium and trapezoid. The scaphoid has an unusual "twisted" shape and orientation [1]. Interposition of the scaphoid within the carpus facilitates wrist mobility and stability but is compensated by increasing the susceptibility of scaphoid to trauma. As the scaphoid is similar to the navicular it is also referred to as carpal navicular but the term is rather misleading. The body of the scaphoid is bean shaped with a dorsal sulcus and a ridge [2]. The bone has six surfaces out which two are non-articular. These non-articular surfaces have multiple arterial foramina. Upto seveaty-five percent of the blood supply is from the branches of the radial artery. In twenty percent of scaphoids, most of the arterial foramina are in the waist area of the bone with no more than a single foramen in the proximal third [3]. Eighty percent of scaphoid bone is consists of cartilage, leaving behind limited space for entrance for the supplying arteries [4]. Scaphoid injury is the most common pathology of the carpal bones [5]. Scaphoid

fractures account for 2% to 7% of all orthopaedic fractures [6], are the most common of all carpal bone fractures and are the most commonly undiagnosed fracture [7]. Scaphoid fractures have produced great confusion in the medical community regarding clinical diagnosis, radiographic evaluation and therapeutic management [8]. Misdiagnosis and improper treatment can result in potentially devastating complications such as delayed fracture union, pseudoarthrosis, avascular necrosis and wrist instability all of which can lead deformity and osteoarthritis [9]. The scaphoid is suspended within the wrist and covered almost completely by cartilage [10]. This configuration is optimal for intricate movements of the wrist joint but rather suboptimal for healing of a scaphoid fracture. A fractured scaphoid unites by primary bone healing with direct formation of bone across the fracture line without external callous formation. Scaphoid nonunions may also develop a problem called avascular necrosis. This can also result in fragmentation and collapse of the bone and may complicate surgical repair of the scaphoid. This study was undertaken to observe the morphometry of the scaphoid waist in Bihar population as very limited documented literature was previously available in the State.

MATERIAL & METHOD

The study included 80 dry human scaphoid bones which were obtained from the department of Anatomy of each of the following medical colleges in Bihar; Katihar Medical College, Indira Gandhi Institute of Medical Sciences and Patna Medical College. Age, sex, side and race were not taken into consideration and only intact bones were observed. Bones with signs of previous fractures and with malformations were excluded from the study. Width of the scaphoid was calculated at the narrowest angle of the waist using thread and then measuring the thread with a ruler.

OBSERVATIONS

Out of 80 scaphoid bones, we observed that only 3 were devoid of waists. Waist circumference was statistically significant. The narrowest waist in the sample was 5.9mm and the widest waist was 7.8mm. Mean waist circumference was recorded to be 6.85mm and SD was 0.98.

DISCUSSION

In this study we observed that the scaphoid waist was absent in three specimens. The scaphoid waist serves as an important anchoring point for several ligamentous attachments [11]. As the waist provides several ligamentous attachments in its absence the attachments could be weak [12]. This may explain higher incidence of ligamentous injuries in scaphoid bones without a waist. Internal fixation has become a well established alternative to casting for acute scaphoid fractures [13]. Screw design has evolved and several different types of screws with varying sizes are now available. Knowing the mean morphometric parameters of the scaphoid in a given population can facilitate the pre-operative selection of a screw of appropriate length for internal fixation. Waist circumference was statistically significant and it may be possible that the scaphoids with waist circumference towards the higher limit could have been of the right hand as Indian population is right dominant. Thus explaining greater force transmission on dominant side according to Wolfe's Law [14]. Future implications of the present study include clinical correlation with the living subjects. Radiological morphometry can be done using CT Scan and the findings of our study can be compared with radiological findings. Our study was limited to the knowledge of age, race, side and sex. This study has thrown some light on the morphometry of the scaphoid bones in Bihar population. A comparative study of morphometry of the scaphoid can be taken up in which data obtained from Bihar can be compared with that of other states. The data obtained from this study and similar studies that shall be taken up in the future will provide useful information to orthopedicians, hand surgeons, chiropractors, radiologists and clinical anatomists.

REFERENCES

1. Kozin SH. Internal fixation of scaphoid fractures. Hand Clin 1997; 13:537-586.
2. Singh HP. Displaced fracture of the waist of the scaphoid. J Bone Joint Surg Br 2011. Nov; 93(11):1433-39.
3. Gelberman RH. The vascularity of the scaphoid bone. J Hand Surg Am1980;5(5):508-513.
4. Rhemrev SJ. Current methods of diagnosis and treatment of scaphoid fractures. Int J Emergency Med 2011;4(4):1-8.
5. Bacorn RW. Colles Fracture. J Bone Joint Surg Br 1953;35:643.
6. Roolker W. The diagnostic management suspected scaphoid fracture. Injury 1997;28:1-8.
7. Nishihara R. The dilemmas of a scaphoid fracture: A difficult diagnosis for primary care physicians. Hospital Physician 2000 Mar;24-40.
8. Waeckerle JF. A prospective study identifying the sensitivity of radiographic findings and the efficacy of clinical findings in carpal navicular fractures. Ann Emerg Med 1987;16:733-737.
9. Southcott R. Nonunion of carpal scaphoid fractures in children. J Bone Joint Surg Br 1977;59:20-23.
10. Dias JJ. Patterns of union in fractures of the waist of the scaphoid. J Bone Joint Surg Br 1989; 71(2):307-310.
11. Berger RA. The ligaments of the wrist. A current overview of anatomy with considerations of their potential functions. Hand Clin 1997; 13:63-83.
12. Purushothama, C. Morphological and morphometric features of scaphoid bone in of north eastern population in India. Nepal Med Coll J 2011; 13(1):20-23.
13. Heinzeimann AD. Anthropometry of human scaphoid. J Hand Surj 2007; 32:1005-8
14. Ceri N. The morphological and morphometric features of the scaphoid. J Hand Surg 2004; 29: 393-8.

Figure:

Image 1 - Scaphoid bone taken for study (77/80 specimens)



Image 2 - Scaphoid bones without waists (03/80 specimens)

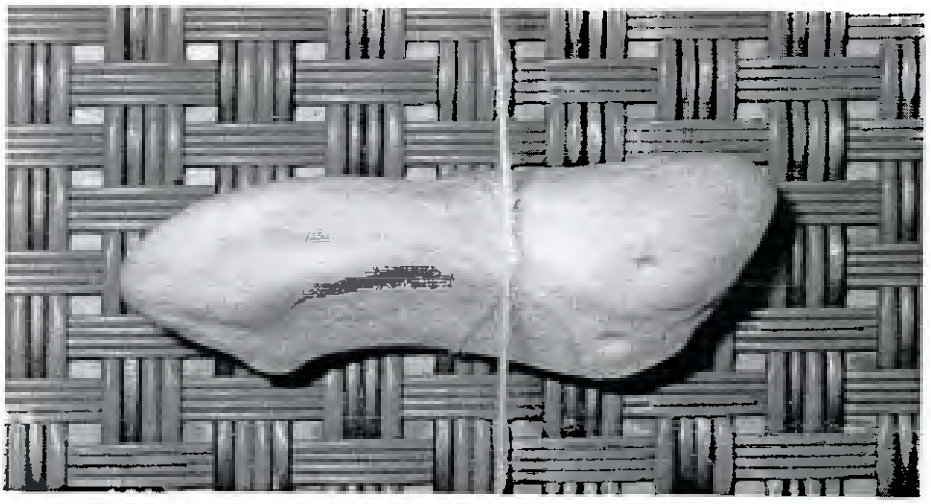

Image 3 - Measurement of Scaphoid waist using thread



Image 4 - Measuring the linear thread against ruler

International Journal of
Recent Scientific Research
ISSN: 0976-3031

Search



CATEGORIES

- Submit Article
- Editors and Reviewers Form
- Editorial Board
- Current Issue
- Special Issue
- Editorial and Publishing Process
- Instruction to Author
- Submissions

TRACKING

- Article Tracking
- Get Your Certificate
- Feedback

AUTHOR INFORMATION

- Model covering Letter
- Model Manuscript
- Copy Right Form
- Sample Certificate
- Membership Application
- Cover page November



SUBJECT AREA

LIFE SCIENCES

- Biological Sciences
- Biotechnology
- Biochemistry
- Genetics
- More→

WELCOME TO IJRSR

Impact Ffactor SJIF 2014 : 5.114
Index Copernicus Value: 5.72

The International Journal of Recent Scientific Research (ISSN 0976-3031) aims at the publication of original research, reviews and short communications on the latest developments in all fields of

Life Sciences: Agricultural, Biological Sciences, Biochemistry, Genetics, Molecular Biology, Environmental Science, Immunology and Microbiology, Neuroscience, Marine Biology.

Physical Sciences and Engineering Chemical Engineering, Chemistry, Computer Science, Earth and Planetary Science, Energy, Mathematics, Physics and Astronomy, Engineering, Material Science, Statistics.

Health Science: Medicine and Dentistry, Nursing and Health Professions, Pharmacology and Toxicology, Pharmaceutical Science, Veterinary Science, Veterinary Medicine.

Social Science and Humanities: Arts and Humanities, Business Management, Management, Accounting, Decision Science, Economics, Econometrics, Finance, Psychology, Social Sciences.

The journal publishes original papers in English which contribute to the understanding of science and Humanities and also developments of the engineering technology and education. Papers may be theoretical, experimental or both. The contribution should be unpublished before and not under consideration for publication elsewhere.

The Journal is a peer reviewed international journal publishing high-quality articles dedicated to all aspects of Science and Humanities and Engineering technology. The Journal considers only manuscripts that have not been published (or submitted simultaneously), at any language, elsewhere. The Journal is issued only in electronic form.

THOMSON REUTERS EndNote

IJRSR OFFERS

- Publication within a short period after acceptance.
- Online tracking of articles submitted
- Online manuscript submission.
- Updates about your manuscript delivered via e mail and SMS
- Peer-Reviewed Open Access Journal.
- Papers abstract/indexed by all the major scientific indexing services.
- Original article will be download (PDF) from the www.recentscientific.com

NEWS & UPDATES

Volume 6, Issue 1-2015

Paper Submission Last Date: Open

Acceptance Intimation: 4-6 Days

Publication Date: Every Month of 28

Call for Papers: January 2015

IMPACT FACTOR

PUBLICATION CERTIFICATE

Email Address

Manuscript No

ARCHIVE

- August 2015
- July 2015
- June 2015
- May 2015
- April 2015
- March 2015
- February 2015
- January 2015
- December 2014
- November 2014
- October 2014
- September 2014
- August 2014
- July 2014
- June 2014

ISSN 0976-3031

Available Online at http://www.recentscientific.com

International Journal of Recent Scientific Research
Vol. 6, Issue, 4, pp.3404-3405, April, 2015

International Journal of Recent Scientific Research

RESEARCH ARTICLE

BILATERAL SYMMETRY OF THE TALUS: A STUDY ON 40 DRY ADULT TALI IN BIHAR

Saif Omar*[1], Masroor Alam[2], Ram Bilash Gupta[3] and Khurshid Alam[4]

[1]Department of Anatomy, Katihar Medical College, Katihar
[2]Department of Orthopaedics, Katihar Medical College, Katihar
[3]Department of Forensic Medicine & Toxicology, Katihar Medical College, Katihar
[4]Department of Anatomy, Patna Medical College, Patna

ARTICLE INFO

Article History:

Received 2nd, March, 2015
Received in revised form 10th, March, 2015
Accepted 4th, April, 2015
Published online 28th, April, 2015

Key words:

Talus, durable, foot, morphometry, Bihar

ABSTRACT

Talus is considered as one of the durable bones of the foot. Researchers in the field of Anatomy, Anthropology and Forensic Medicine have performed numerous studies on talus. This study is designed to evaluate Talar length (Tl) Talar width (Tw) and Talar height (Th) from forty intact dry adult tali. This study aims to throw some light on morphometry of Talus bone in the state of Bihar and contribute to anatomic and forensic literature.

INTRODUCTION

The human foot is a highly developed biomechanically complex structure that serves to bear the weight of the body. About 26 bones in the foot play an integral role in providing structural support. They can be grouped conveniently as follows, Tarsals (7); Metatarsals (5) and Phalanges (14). Apart from these bones, there exist certain sesamoid bones which help to improve the functions of the foot. For descriptive purposes, the foot can be divided into a hindfoot containing the talus and calcaneus, a midfoot containing the cuboid, navicular and cuneiforms and a forefoot containing the metatarsals and phalanges. The word talus is derived from the Latin word *taxillus*, which refers to ankle bone of a horse. These bones were used as playing dice by Roman soldiers [1]. The talus is the second largest tarsal bone and has a unique structure designed to channel and distribute body weight [2]. Approximately 60% of its surface is covered by articular cartilage and there are no muscular or tendinous attachments to this bone [3]. Consequently, only a limited area of penetrable bone is available for vascular perforation. The talus has been extensively studied. Ossification of the talus originates from a single primary center that induces elongation in an anteroposterior direction [4].The talus as an entity articulates with navicular, calcaneum, tibia and fibula. The body of the talus is uniquely shaped being wider anteriorly and narrower posteriorly. The talar neck has a roughened appearance and paucity of cartilage due to multiple ligamentous insertions. The head is a convex structure with numerous articulations. Talus has also been studied by many researchers specially the presence of squatting facets [5]. Variations in talar anatomy can be of help for reconstruction and rehabilitation of foot [6]. Measures of cranium, pelvis and long bones are used to evaluate population, gender and age. However, it may also be required to use other bones in the researches using bone pieces instead of the entire bone [7]. The body and the neck of the talus are not coaxial. In the horizontal plane, the neck shifts medially and makes an angle of declination (AD) with the long axis of the trochlear tali; this angle is variable [8]. In the sagittal plane the neck is deviated downward relative to the talar body and makes an angle of inclination (AI) [9]. The talus is a good example of plasticity exhibited by bones in response to mechanical requirements of new functions, which are imposed on it, as the talus encounters several differential forces during locomotion [10]. The stress patterns across the talus influence its overall dimensions and articular surface areas.

MATERIAL AND METHOD

The study included 20 pairs of intact dry adult tali, which were obtained from the department of Anatomy of each of the following medical colleges in Bihar; Katihar Medical College and Patna Medical College. Age, sex, and race were not taken into consideration and bones with signs of previous fractures

Corresponding author:* **Saif Omar
Department of Anatomy, Katihar Medical College, Katihar

and other malformations were excluded from the study. Talar length (Tl) Talar width (Tw) and Talar height (Th) were measured using sliding Vernier calipers with an accuracy of 1mm. Bilateral differences if any were evaluated statistically.
Image 1 = Measurement of Tl
Image 2 = Measurement of Tw
Image 3 = Measurement of Th

Observation

Observations and comparisons are represented in Tables 1&2.



Table1 Measurement values of Talus bone

Parameter	Side	N	Mean	SD*	SEM#
Tl	R	20	5.31cm	0.37	0.08
Tl	L	20	5.31cm	0.34	0.08
Tw	R	20	4.02cm	0.24	0.05
Tw	L	20	4.02cm	0.26	0.06
Th	R	20	2.93cm	0.22	0.05
Th	L	20	2.93cm	0.24	0.05

SD* = Standard Deviation
SEM# = Standard Error of Mean

Table2 Comparison of parameters with other related studies

Authors	Mean Tl (R)	Mean Tl (L)	Mean Tw (R)	Mean Tw (L)
Ari *et al*	5.72 cm	5.64 cm	4.91 cm	4.69 cm
Mahato *et al*	5.57 cm	5.58 cm	2.90 cm	3.03 cm
Gautham *et al*	5.23 cm	5.29 cm	3.79 cm	3.68 cm
Motagi *et al*	5.42 cm	5.33 cm	3.62 cm	3.77 cm

DISCUSSION

Talus is a bone, which is used to determine unknown skeletal remains during archaeological and forensic science excavations due to its durability [11]. Talus is the key bone of the human body as it transmits the entire body weight. Since the talus endures many differential forces during locomotion, the stress patterns across the talus influence its overall dimensions [12]. Variations in Talar length (Tl), Talar width (Tw) and Talar height (Th) among different populations can reveal certain habitual activities that an individual in that population is engaged in. The above-mentioned findings can be useful in determining the race of unidentified bones. In the present study, we observed that there were no significant side related differences in the tali. We conclude that both tali in an intact skeleton are relatively similar and strongly symmetrical. Further, this study may be helpful for orthopaedic surgeons during surgical interventions on traumatic talus and for prosthetists during designing of talar prosthesis.

References

1. Appleton AB. Postural deformities and bone growth. Lancet 1934; 224:451-454.
2. Berlet GC. Talar neck fractures. Orthop Clin North Am 2001; 32: 53-64.
3. Berquist TH. Radiology of the foot and aknkle. 2nd ed. Philadelphia, PA: Lippincott Williams & Wilkins, 2000; 218-224.
4. Haubrich WS. Medical meanings: A glossary of word origins. Philadelphia, PA: American College of Physicians, 1997; 253.
5. Iqbal K. Anatomical variations of trochlear surface of talus. JUMDC Vol. 3, Issue 1, Jan-Jun 2012.
6. Kottapurath RS. Morphometric analyses of human dry tali of South Indian origin. *Int J Med Sci Public Health* 2015; 4:237-240.
7. Motagi MV. Morphometric analyses of human dry tali of South Indian origin. *Int J Med Sci Public Health* 2015; 4:237-240.
8. Otag I. Morphometric measures of talus bone in skeleton remains belonging to Antolian geography. *Indian J Applies Res.* 2013; 3(8): 530-531.
9. Pearce DH. Avascular necrosis of the talus: A pictorial essay. RadioGraphics 2005; 25:399-410.
10. Sarrafian SK. Anatomy of the foot and ankle: Descriptive, Topographic, Functional. Philadelphia, PA: Lippincott, 1983. pp 400-407.
11. Singh I. Squatting facets on the talus and tibia in Indian foetuses. *Acta anatomica* 1963; 54: 137-144.
12. Steele DG. The estimation of sex on the basis of talus and calcaneus. *Am J Phy Anthropol* 1976; 45:581-588.

****

International Journal of Research in Medical Sciences
Alam M et al. Int J Res Med Sci. 2016 Jan;4(1):38-41
www.msjonline.org
pISSN 2320-6071 | eISSN 2320-6012

DOI: http://dx.doi.org/10.18203/2320-6012.ijrms20151536

Research Article

Incidence, diagnosis and management of adult cases presenting with symptomatic lumbar spondylolisthesis in a tertiary care hospital

Masroor Alam[1], Wasim Bari[2], Saif Omar[3]*

[1]Associate Professor, Department of Orthopaedics, Katihar Medical College, Katihar, Bihar, India
[2]RMO cum Clinical Tutor, Department of Orthopaedics, Murshidabad Medical College, Berhampore, West Bengal, India
[3]Associate Professor, Department of Anatomy, Katihar Medical College, Katihar, Bihar, India

Received: 06 December 2015
Accepted: 15 December 2015

***Correspondence:**
Dr. Saif Omar,
E-mail: drsaifomar@gmail.com

ABSTRACT

Background: Five lumbar vertebrae bridge between the thoracic and the sacral. The first four are typical in nature and the fifth is of a standalone atypical variety. Normal inward curvatures are observed in both cervical and lumbar regions of the vertebral column. These lordotic curvatures usually help in shock absorption and support the weight of the head. Spondylolisthesis occurs when one vertebra slips forward over the vertebra below it. This condition usually develops in the lumbar region of the vertebral column. It is due to the lumbar spine being exposed to directional pressures while carrying and distributing most of the body weight during activity and at rest. Such a combination of weight bearing and multidirectional movement may cause forward slippage of any random lumbar vertebra over the vertebra beneath it. The aim of this study was to observe retrospectively adult male and female cases presenting with spondylolisthesis in the outdoor clinic of the Department of Orthopaedics in a tertiary care hospital.
Methods: Adult cases of either sex presenting with low back pain were clinically and radiologically investigated. Data regarding age, sex and occupation were recorded.
Results: The incidence of symptomatic spondylolisthesis was reported to be 211 out of 5117 cases that presented with low back pain. We observed that majority of cases were in the age group of 23 to57 years with higher preponderance among males. A small fraction of presenting cases were advised for laminectomy.
Conclusions: Incidence of symptomatic lumbar spondylolisthesis was high. Sex ratio among presenting cases was observed to be higher in males. Cases were clinically examined and diagnosed radiologically. Most cases were managed conservatively.

Keywords: Laminectomy, Lordotic, Lumbar, Slippage, Spondylolisthesis, Vertebra

INTRODUCTION

Low back pain disorders are an increasingly common condition involving visits to the orthopaedic clinic. Cases presenting with low back pain are predominantly concerned with being able to return to work in shortest possible time. Five massive lumbar vertebrae constitute an important bony bridge connecting the thoracic spine to the sacrum. These vertebrae are designed and adapted to and transmit the body weight in addition to movement. Spondylolisthesis is a clinical ortho-neurological disorder involving slippage of one vertebral body over another, usually resulting in low back pain. The term is derived from two Greek words *spondylo* (vertebra) and o*listhenein* (to slip).[1] The first written description of spondylolisthesis is attributed to Herbiniaux, a Belgian obstetrician, who in 1782 described an osseous prominence anterior to the sacrum that caused narrowing of the birth canal.[2] Forward slippage of a vertebra is termed anterolisthesis while backward slippage is referred to as retrolisthesis.[3] The fifth lumbar vertebra is the most commonly affected vertebra usually after a

break or fracture.[4] Incidence of this condition varies according to age, sex, association with certain diseases, trauma and occupation. It can be classified as either asymptomatic or symptomatic. Prevalence of the condition has been reported to be 5-7% in American population.[5-10] Lumbar spondylolisthesis is a major cause of spinal canal stenosis and is often related to low back and leg pain.[11] The most common site of spondylolisthesis is at the L_5-S_1 level because of an L_5 pars defect. Spondylolisthesis has never been recognized in any species other than humans. It is believed that the development of spondylolisthesis is related to man's ability to maintain an erect posture and the development of lumbar lordosis, the latter being unique to humans.[12,13]

Classification of spondylolisthesis (Marchetti & Bartolozzi)[1]

Developmental:

a) High Dysplastic
   - With Lysis
   - Without Lysis

b) Low Dysplastic
   - With Lysis
   - Without Lysis

Acquired:

a) Traumatic
   - Acute
   - Stress

b) Post Surgery
   - Direct Surgery
   - Indirect Surgery

c) Pathological
   - Local Pathology
   - Systemic Pathology

d) Degenerative
   - Primary
   - Secondary

Classification of spondylolisthesis (Herman & Pizzutillo).[1]

Type I = Dysplastic
Type II = Developmental
Type III = Traumatic
   - Acute
   - Chronic

Type IV = Pathological

Most commonly used radiographic grading system for spondylolisthesis is that of Meyerding. In this system slip grade is calculated by determining the ratio between the anteroposterior diameter of the top of the first sacral vertebra and the distance the L5 vertebra has slipped anteriorly.

Grade I = Displacement of 25% or less
Grade II =Displacement between 25% to 50%
Grade III =Displacement of between 50% to 75%
Grade IV = Displacement more than 75%
Grade V = Position of the L5 vertebra completely below top of sacum (Spondyloptosis)

In analysing spondylolisthesis the surgeon must first decide of the condition is developmental or acquired. The degree of lordosis, position of the gravity line and competency of the disc at the level of spondylolisthesis is also important. Restoration of spinopelvic balance is important in the treatment of spondylolisthesis.

METHODS

After prior approval from the Institutional Ethics Committee (IEC), this study was conducted in the Department of Orthopaedics. All adult cases of either sex and between the ages of 18 to 60 years that presented to the outdoor clinic with symptomatic low back pain were enrolled in this study. Data pertaining to age, sex and occupation of the patient was documented and each patient was clinically and radiologically examined. Cases not falling in the age group, cases with past history of spinopelvic fractures and pregnant cases were excluded from the study. Diagnosed cases of spondylolisthesis were managed conservatively and reviewed.

RESULTS

A total number of 5117 orthopaedic cases as demarcated, presenting with symptomatic low back pain were examined during the study period, out of which 211 (4.12%) cases were diagnosed with symptomatic spondylolisthesis as shown in Table 1. Out of 211, number of males and females were 122 (57.8%) and 89 (42.2%) respectively with a sex ratio of 1.37:1 being higher among males (Table 2). Majority of the cases presenting with symptomatic spondylolisthesis were in the age group of 23-57 years (Table 3). Out of 211 diagnosed cases only 17 (8.1%) were recommend for surgery and remaining were managed conservatively with moderate to satisfactory improvement observed during follow up.

Table 1: Incidence of symptomatic spondylolisthesis in this study.

No. of cases diagnosed	Total no of cases studied	Incidence (%)
211	5117	4.12

Table 2: Prevalence between both sexes in this study.

No. of cases diagnosed	Total no of male cases	Total no of female cases
211	122 (57.8%)	89 (42.2%)

Table 3: Distribution of cases between both sexes in specified age groups.

Age (Yrs)	No. of cases (Males)	Age (Yrs)	No. of cases (Females)
18-24	07	18-24	06
25-31	15	25-31	11
32-38	19	32-38	09
39-45	23	39-45	23
46-52	31	46-52	21
53-59	27	53-59	19

DISCUSSION

Spondylolisthesis is a complex and challenging multifactorial condition. Spondylolisthesis is the forwards slippage of one vertebra on another and may be the result of a spondylosis.[14] In this study, we observed an incidence of 4.12% with the condition being higher in males than in females. Our incidence can be contrasted with that in the US.[15-20] The natural history of this condition is favourable, as only 10-15%, cases seeking treatment will eventually have surgery.[21] Spondylolisthesis is easily recognized yet confusion persists over its natural history and preferred treatment. A better understanding of the natural history and disease pathogenesis is required to allow an evidence based approach to the management of spondylolisthesis. Diagnosis of this condition is rather simple and mainly based on imaging. The incidence of spondylosis is 5-6% in the general population, however the increased prevalence upto 12% is noted in adolescents with Scheuman's disease, weight lifters, athletes such as football linemen and gymnasts, signifies that mechanical factors may be important in the aetiology of this condition.[22] Although many surgical techniques being available it is implied to opt for conservative management before implementing surgical intervention. Specific aims of nonsurgical treatments should focus on improvement of spinal segmental stability and relieving of symptoms due to spinal cord compression. In this study, we observed that incidence was higher in males. In males, maximum number of cases was in the age group 46-52 years. In females, maximum numbers of cases were in the age group 39-45 years. Depending on the severity of the case, we suggested physiotherapy with mild to moderate lifestyle changes and recommended exercises on a daily basis. Several studies suggest a congenital predisposition to spondylosis, with prevalence of 27-69% among family members of the affected individuals.[23] In the adult population, stenosis is more of a feature with pain due to degenerative changes more prevalent.[24,25] The most commonly involved vertebrae are L_4 and L_5, which are the keystones of lumbosacral spine providing stability by supporting physiological loads and preventing unnecessary motion.

CONCLUSION

Understanding the multifactorial aetiology plays an important role in both conservative and surgical management of cases presenting with symptomatic lumbar spondylolisthesis. Nonoperative treatment is successful in most cases. Surgical intervention should be recommended in cases where radiating pain does not subside along with manifestation of bowel and bladder symptoms. Imaging remains the only accurate tool for understanding of tissues involved and to facilitate neurosurgery related decision making. Spondylolisthesis can be visualized using standard lateral films and oblique radiographs are best for detection. Radiographs taken in the position of maximum pain are also recommended. CT Scans and MRI Scans may be used preoperatively to assess the neurological compression, surrounding soft tissues and bony anatomy. Creating awareness about a healthy spine, spine injuries and prevention of spine related diseases can also prove beneficial.

Funding: No funding sources
Conflict of interest: None declared
Ethical approval: The study was approved by the Institutional Ethics Committee

REFERENCES

1. Canale TS. Campbell's Operative Orthopaedics, Vol-II, 12th ed. Canada: Elsevier-Mosby; 2013:1839.
2. Ganju A. Isthmic spondylolisthesis. Neuorosurg. Focus. 2002;13:1-6.
3. Kuubiere CB. Incidence of symptomatic spondylolisthesis in Northern Ghana. Al Ameen J Med Sci. 2005;8(4):254-8.
4. Gibson JNA. Surgery for degenerative lumbar spondylosis. Spine. 2005;30(20):231-5.
5. Metsunaga S. Natural history of degenerative spondylolisthesis. Pathogenesis and natural cause of the slippage. Spine. 1990;15(11):1204-10.
6. Sengupta DK. Degenerative spondylolisthesis; Review of current trends and controversies. Spine. 2005;30(6 Suppl):71-81.
7. Ikuta K. Short term results of microendoscopic posterior decompressionfor lumbar spinal stenosis. J Neurosurg Spine. 2005;2(5):624-33.
8. Rahman M. Comparison of techniques for decompressive laminectomy; the minimally invasive versus the classic open approach. Minimally Invasive Neurosurg. 2008;51(2):100-5.
9. Atlas SJ. Long term outcomes of surgical and non-surgical management of lumbar spinal stenosis. Spine. 2005;30(8):936-43.
10. Lee CK. Lumbar spinal instability after extensive posterior spinal decompression. Spine. 1983;8(4):429-33.

11. Kalichman L. Diagnosis and conservative management of degenerative lumbar spondylolisthesis. Eur Spine J. 2008;17:327-35.
12. Rowe GG. The etiology of separate neural arch. J Bone Joint Surg Am. 1953;35:102-10.
13. Scott JH. Inheritance and spondylolisthesis: A radiographic family survey. J Bone Joint Surg Br. 1979;61:301-5.
14. Sadiq S. Surgical management of spondylolisthesis overview of literature. Neurology India. 2005; 53(4):506-11.
15. Martin CR. The surgical management of degenerative lumbar spondylolisthesis: a systematic review. Spine. 2007;32(16):1791-8.
16. Surin V. Degenerative lumbar spinal stenosis, result of operative treatment. Acta Orthop Scand. 1982;33(1):79-85.
17. Beutler WJ. Natural history of spondylosis and spondylolisthesis: a 45year follow up evaluation. Spine. 2003;28(10):1027-35.
18. Wiltse LL. Spondylolisthesis: Classification and aetiology. Symposium of the spine. Am Acta Orthop Surg. 1969:143.
19. Grobler LJ. Classification of operative and non-operative treatment of spondylolisthesis. In: Frymoyer's The Adult Spine: Principle & Practice. 2nd ed. Philadelphia. Lippincott. 1997:1865-921.
20. Mackay M. Degenerative lumbar spondylolisthesis, a prospective randomized study comparing decompressive laminectomy and arthrodesis with and without spinal instrumentation. Spine. 1997;22(24):2807-12.
21. Faldini C. Surgical Treatment of symptomatic degenerative lumbar spondylolisthesis by decompression and instrumented fusion. J Orthop Traumatol. 2007;8(3):128-33.
22. Baker D. The natural history of spondylosis and spondylolisthesis. J Bone & Joint Surg Br. 1979;61:301-5.
23. Albanese M. Family study of spondylosis and spondylolisthesis. J Paeditr Orthop. 1982;2:496-9.
24. Hammerberg KW. New concepts on the pathogenesis and classification of spondylolisthesis. Spine. 2005;30(Suppl):4-11.
25. Buck JE. Direct repair of the defect in spondylolisthesis with the modifies Boston brace. J Bone & Joint Surg Br. 1970;52:432-7.

Cite this article as: Alam M, Bari W, Omar S. Incidence, diagnosis and management of adult cases presenting with symptomatic lumbar spondylolisthesis in a tertiary care hospital. Int J Res Med Sci 2016;4:38-41.

International Journal of Research in Medical Sciences
Bari W et al. Int J Res Med Sci. 2015 Dec;3(12):3482-3484
www.msjonline.org
pISSN 2320-6071 | eISSN 2320-6012

DOI: http://dx.doi.org/10.18203/2320-6012.ijrms20151242

Research Article

Goniometry of elbow carrying angle: a comparative clinical study on sexual dimorphism in young males and females

Wasim Bari[1], Masroor Alam[2], Saif Omar[3]*

[1]RMO Cum Clinical Tutor, Department of Orthopaedics, Murshidabad Medical College, Berhampore, West Bengal, India
[2]Associate Professor, Department of Orthopaedics, Katihar Medical College, Katihar, Bihar, India
[3]Associate Professor, Department of Anatomy, Katihar Medical College, Katihar, Bihar, India

Received: 21 October 2015
Accepted: 07 November 2015

***Correspondence:**
Dr. Saif Omar,
E-mail: drsaifomar@gmail.com

ABSTRACT

Background: Carrying angle of the elbow joint is an angle formed between the axis of arm and axis of forearm in an extended elbow joint supinated at the radio-ulnar joints. It is an obtuse angle which facilitates free swinging of arm by deviating it from the pelvis during walking or carrying an object. Carrying angle increases with age and is reportedly greater in females. Morphometry of this angle may be helpful in identification of elbow disorders along with surgical reconstruction and evaluation of traumatic elbow. The aim of this study was to clinically observe sexual dimorphism of carrying angle among young males and females with normal anatomy and bony configuration of elbows between 21 to 25 years of age the in the outdoor clinic of the Department of Orthopaedics.
Methods: Four hundred individuals of equal sex ratio underwent bilateral goniometry. The measurement of carrying angle was performed using goniometer.
Results: Carrying angle was observed to be greater in females. There was no correlation between carrying angle and height of individual or length of forearm.
Conclusions: Carrying angle is greater in females may be because exhibits high sexual dimorphism. It may also considered be as a secondary sexual characteristic. Utility of goniometry of carrying angle is observed during orthopaedic reconstruction of elbow disorders after treatment of distal fractures of humerus and evaluation of traumatic injuries at the elbow joint.

Keywords: Carrying angle, Elbow, Goniometry, Sexual dimorphism, Trauma

INTRODUCTION

The elbow joint is a uniaxial, synovial joint of hinge variety. The lower end of the humerus articulates with the upper ends of both radius and ulna. Flexion and extension are the two movements occurring at this joint. Proximal to the elbow joint lies another synovial joint of pivot variety at which movements of pronation and supination occur. It should be noted that the long axis of the extended forearm lies at an angle to the long axis of the arm. This angle which opens laterally is called the carrying angle and is about 170° in the male and 167° in the female.[1] The angle disappears when the elbow joint is fully flexed. The carrying angle apparently develops in response to pronation of the forearm and keeps the swinging upper extremity away from the side of the pelvis during walking.[2,3] Factors responsible for production of carrying angle are the medial flange of trochlear is 6mm deeper than the lateral flange and the superior articular process of the coronoid process of the ulna is placed oblique to the long axis of the bone.[4] Clinically the carrying angle of the elbow joint is

assessed by radiographs to evaluate the reduction of distal humerus or radial head fractures and epicondylar pathologies.[5] Studies have also revealed that due to greater depth of inner lip of trochlea of humerus the ulna is deflected in full extension. Carrying angle is the result of the inner condyle of the humerus being set obliquely so that the axis of the elbow joint is transverse between the radius and humerus but oblique between the ulna and the humerus.[6] The carrying angle varies markedly between individuals and tends to be greater in females versus males and greater in adults versus children.[7] Structurally, women on an average have smaller shoulders and wider hips than their male counterparts which may be one appropriate reason for having an acute carrying angle. The olecranon coronoid angle shows high sexual dimorphism and it may be one of the causes of sexual difference observed in carrying angle.[8] Handling and monitoring of traumatic paediatric elbow injuries often require evaluation of the carrying angle. Forensic anthropologists may utilize knowledge of carrying angle to ascertain the sex of an individual from skeletal remains and biomechanical engineers may require knowledge of the same for designing a total elbow prosthesis.[9]

METHODS

After prior approval from the Institutional Ethics Committee (IEC), a total of eight hundred elbows of four hundred healthy, asymptomatic, young males and females in equal sex ratio with normal bony configuration in the age group of 21 to 25 years were examined in the Department of Orthopaedics. Handedness was not a factor in this study. Persons with shoulder or elbow or wrist pathologies, asymmetry, congenital malformations, history of elbow surgery and amputees of upper limbs were excluded from the study. Participants were seated on a fixed chair and bony landmarks were identified through palpation and marked with a skin pencil. The bony landmarks were olecranon process of the ulna, head of the radius, medial and lateral epicondyles of humerus and head of ulna. During measurement each forearm of the individual was extended, supinated and fixed. The fixed arm of the goniometer was placed on the median axis of the arm and the movable arm was placed on the median axis of the forearm. The angle was measured and read by two observers to avoid interobserver disparity. Data collected was recorded and analysed statistically.

RESULTS

In this study we observed that there were no significant differences between carrying angles of both sides of the same person. Significantly greater carrying angles were observed in females. No correlation could be established between length of the forearm and carrying angle in either sex. Carrying angles were observed to be 13.88±3.46° in females and 12.18±2.62° in males.

Table 1: Sex ratio of participants involved in this study.

n	Males	Female
400	200	200

Table 2: Distribution of participants according to age.

Age in Years	No. of males	No. of females
21	27	31
22	32	33
23	39	37
24	47	44
25	55	55

Table 3: Carrying angle observed according to sex after goniometry.

Carrying angle	Group
12.18 ± 2.62°	Males
13.88 ± 3.46°	Females

DISCUSSION

Evolution of the upper limb has resulted in two contrasting features that supersede it from the lower limb. They are rotation of the thumb for grasping and rotation of the forearm during supination-pronation complex. Evolution of a carrying angle in apes is related to the need to bring the centre of the mass of the body beneath the supporting hand during suspensory locomotion as seen in lower limbs of humans in which the valgus knee brings the foot nearer to the center of mass of the body during the single limb support phase of walking.[10] The evaluation of carrying angle of elbow and knowledge of its variations is essential for the handling and monitoring of traumatic lesions.[11] In physiologic conditions this parameter varies according to age, gender, hyperextension of the elbow, dominant upper limb, anthropometric characteristics such as height and intertrochanteric distance.[12-15] We observed mean values to be 12.18±2.62° in males and 13.88±3.46° in females. Some researchers are of the opinion that elbow carrying angle values are higher on the dominant side, yet we did not encounter such a correlation in our study.[16] Carrying angle has been reported to increase with age and because of skeletal maturation and is always greater on the dominant side.[17,18] As our age group was small, we could not document any data on change of carrying angle with age. We also observed that although length of the forearm bones is longer in males the carrying angle is however higher in females. Goniometry of the carrying angle has clinical significance as an increased carrying angle may be a risk factor for non-traumatic ulnar neuropathy. Reproduction of carrying angle measurement is easily applicable in routine orthopaedic practice however others challenge that its applicability is of little practical importance and maximum extension of the elbow should contribute to the increase of the elbow carrying angle.[19,20]

CONCLUSION

Carrying angle is greater in females than in males and it may be considered to be a secondary sex characteristic in the female. This angle may be high in females due to laxity of articular ligaments, larger breasts and a wider pelvis which may result in a greater lateral deviation of the forearm on the arm. Carrying angle is an important anatomic feature when restoration of the elbow's function is required. Another application of goniometry of the carrying angle would be to evaluate the possible genesis of specific fractures of the elbow region. Clinical correlation of carrying angle helps orthopaedic and trauma surgeons during correction of deformity occurring after malunited supracondylar fracture of humerus. Carrying angle values and its pathologic variants are important in the management of elbow fractures and in the diagnosis of diseases of the lateral and medial epicondyles.

Funding: No funding sources
Conflict of interest: None declared
Ethical approval: The study was approved by the Institutional Ethics Committee

REFERENCES

1. Snell RS. Clinical Anatomy by Regions, 9th ed. Philadelphia, PA: Lippincott Williams & Wilkins. 2012: 408.
2. Khare GN. New observations on carrying angle. Ind J Med Sci. 1999;53:61-7.
3. Kothapalli J. The carrying angle of elbow – A correlative and comparative study. Int J Cur Res Rev. 2013;5(7):71-6.
4. Garg K. B D Chaurasia's Human Anatomy, Vol-I, 4th ed. India: CBS Publishers & Distributors. 2007:149.
5. Zampagni ML. Estimating the elbow carrying angle with an Electrogoniometer: Acquisition of data and reliability of measurements. Healio Orthop. 2008;31(4):1-9.
6. Decker GAG. Lee McGregor's Synopsis of Surgical Anatomy, 12th ed. India, Varghese Publishing House. 1995:454.
7. Clippinger KS. Dance Anatomy & Kinesiology, 2nd ed. Human Kinetics. 2006:413.
8. Cain EL. Elbow injuries in throwing athletes: A current concepts review. Am J Sports Med. 2003;31:621-35.
9. Hutchinson MR. Biomechanics and development of the elbow in the young throwing athlete. Clin Sports Med. 2004;23:531-44.
10. Cwirko-Godycki M. Sexing skeletal remains. The human skeleton in forensic medicine. 3rd ed. 1978:112-52.
11. Balasubramanium P. Carrying angle in children. A normative study. J Paed Orth B. 2006;15:37-40.
12. Beals RK. The normal carrying angle of the elbow. A radiographic study of 422 patients. Clin Orth Rel Res. 1976;119:194-6.
13. Golden DW. Elbow range of motion and clinical carrying angle in a healthy paediatric population. J Paed Orth B. 2007;16:144-9.
14. Demirel H. Measurement of the carrying angle of the elbow in 2000 children at ages six and fourteen years. Acta Orthop Traumatol Turc. 2004;38:274-6.
15. Paraskevas G. Study of the carrying angle of the human elbow joint in full extension: A morphometric analysis. Surg Radiol Anat. 2004;26:19-23.
16. Terra BB. Evolution of the carrying angle of the elbow: A clinical and radiographic study. Acta Orthop Bras. 2011;19(2):79-82.
17. Emami MJ. Normal carrying angle of the elbow. Shiraz Mijri. 1998;12(1):37-9.
18. Dai L. Measurement of the Baumann angle in Chinese children and its clinical relevance. J Paed Orthop B. 1999;8:197-9.
19. Morrey BF. Carrying angle of the human elbow joint. J Orth Res. 1984;1:369-78.
20. London JT. Kinematics of the elbow. J Bone Joint Surg Am. 1981;63(4):529-35.

Cite this article as: Bari W, Alam M, Omar S. Goniometry of elbow carrying angle: a comparative clinical study on sexual dimorphism in young males and females. Int J Res Med Sci 2015;3:3482-4.

Evaluation of Locking Compression Plate (LCP) in the Management of Bones of Upper and Lower Limbs

Md. Mohtashemul Haque[1], Dr. Raj Kumar Singh[2]

INTRODUCTION

Upper and lower limb bones are the building blocks and owing to the location and their use long bones are exposed to frequent injury. Any kind of derangement in the skeletal system (mostly long bones) either structural or functional, leads to deformity or disability in the body. It is generally accepted that the early definitive treatment, of long bone fractures should be carried out to prevent complications such as joints stiffness, delayed union, non-union, shortening of limb, neurovascular injury, thrombo-embolism, muscle atrophy, bed sore and even death.

The method of choice for treatment of long bone fractures should be such that it provides secure fixation and early mobilization, allows functional use of the limb after treatment, should not interfere with healing. In children, the treatment should be such that there is no or minimal growth plate damage.

Conservative treatment of long bone fractures using traction, cast or functional bracing has been described with good end results. However, this type of treatment does not allow early mobilization neither it takes into account the group of patients who are victims of polytratuma. The rapid industrialization, urbanisation and rapid increase in the number of automobiles has led to a remarkable increase in the number of polytrauma cases and there is increase in demand for operative techniques, which are minimally invasive, less cumbersome, requires less operative time, leading to early return to normal life and the same time they are economical also.

Locked plates are of two types: (1) Simple locked plate eg PC-Fix and LISS and (2) Locking compression plate. Simple locked plate is not technically feasible to be applied in transverse or short oblique type of fractures where compression is needed at fracture site.

A newer concept of internal fixation, the locking compression plate (LCP) was introduced to overcome the drawbacks of conventional and simple locked plating system. The initial idea of LCP, which was based on LC-DCP and PC-Fix or LISS came from Prof. Michael wagner (1998) from Vienna. Robert Frigg (2000) an engineer from Mathys Medical in Bettlach, who actually designed, constructed and tested the unique combination hole. The unique design of these combination holes allows the system to be used both as a conventional compression plate and as a locked internal fixator; it also allows internal fixation with a combination of conventional and locking head screws.

AIMS AND OBJECTIVES

In this project an attempt has been made to analyse the procedure and evaluate the results of locking compression plate, as a fixation device in the treatment of fractures of long bones of upper and lower limbs in terms of anatomical and functional results.

MATERIAL AND METHODS

The present study **"EVALUATION OF LOCKING COMPRESSION PLATE (LCP) IN MANAGEMENT OF FRACTURE OF BONES OF UPPER AND LOWER LIMBS"** was carried out in the Department of orthopaedics, Katihar Medical College and Hospital, Katihar, Bihar.

Selection of patients :

LCP plating was performed on patients with fracture of long bones using following criteria.

1. Fractures in the osteoporotic bones.
2. Comminutted shaft and metaphyseal fractures.
3. Extension of fracture into joint.
4. All closed fractures of long bone (Femur, Tibia, Humerus, Radius and Ulna).
5. Grade I and II open fractures
6. Pathological fractures.
7. Delayed Union/Non union/Malunion
8. Refracture of an original fracture that had already been treated with some other implants.
9. Broken nails.
10. Fracture with narrow as well as very large medullary canals.

Materials:

1. Locking compression plate of different shape and size according to anatomical site and type of fracture.
2. Locking screw of 3.5mm, 4.0 mm, 4.5 mm, 5 mm and 6.5 mm with variable length.
3. Conventional screws
4. K. wire of 1.6 to 2.0 mm
5. Threaded drill guide
6. Drill bit
7. Tap
8. Depth gauze
9. Screw driver
10. Electric/hand drill
11. Plate clamp, bone clamp and reduction clamp.

1. M.S. (Ortho.), Assistant Professor, Department of Orthopaedics, K.M.C.H., Katihar, Bihar
2. M[illegible] (Ortho.), Senior Resident, Department of Orthopaedics, K[illegible]., Katihar, Bihar.

12. All components were available in 316L stainless steel.

13. General surgical instruments.

14. General orthopaedics instruments.

15. Image intensifier/portable X-ray.

Method:

After thorough clinical and radiological examination, the fractured limbs were kept in POP slab or on traction, as required.

All routine and special investigations were performed and patients were prepared for LCP plating.

General Examination

Local Examination

Investigations

Operative planning

Operative procedure

Post Operative Management

Observational parameters

Clinical evaluation

Radiological evaluation

RESULTS

A total of 35 fractures of long bones in 35 patients were evaluated, investigated, treated and subsequently followed for maximum period of 24 weeks to evaluate the effectiveness of LCP in the management of fractures of long bones.

The age of the patient ranged from 19-70 years with an average of 36.91 years. The maximum number of patients was in the age group of 31-40 years. This age group is considered to be most active. There were 29 males and 6 females constituting Male : Female ratio of 4.83 : 1. This goes with the socio-economic condition of this country. Males are more involved in our-door activities. There were 7,6,4,6, and 12 cases of humerus, radius, ulna, femur and tibia respectively.

Right sided injuries were more common because of cerebral cortex dominance. The most common mode of injury was road traffic accident, followed by fall from height. Majority of cases were isolated fractures of long bones. 60% of the fractures were in the middle third of the long bones.

There were 29 closed fractures, 2 open grade-I and 4 open grade-II fractures. Of 30 fresh fractures, 17 were simple, most common was transverse type. While 13 fractures were comminuted type.

In our study out of 35 cases of fractures of long bones, 5 cases were of non-union. Out of 5 cases, 3 cases of non union were treated conservatively, 1 case by DFN and 1 case with DCP initially. In all the cases of non-union LCP with cancellous bone grafting were done. In majority of cases(82.86%), LCP were applied by open method while in 17.14% of cases MIPO technique were used. There were 3 cases of superficial infection in fracture tibia. Of these 1 case was open grade-II and 2 cases were of closed type. Active non-weight bearing physiotherapy of the joint concern was started from 4th post operative day. Patients usually gained full ranged of motion at the joints concerned, at the end of 2nd week in case of upper limb while for lower limb full range of motion was achieved in 6 to 7 weeks. In our study only 3 cases developed terminal restriction of movement, which latter on improved by physiotherapy. Partial use of upper limb were allowed after 3 to 4 weeks time, while for lower limb partial use (partial weight bearing) were allowed after 6 to 7 weeks. Visible callus was noted at 3 weeks in 3 patients. Exuberant callus was present in all the cases of upper limb at 24 weeks. While in case of lower limb exuberant callus was present in all the cases at 36 weeks.

Local bony tenderness was absent at 6 weeks in 6 cases. At 12 weeks bony tenderness was absent in 27 cases. At 36 weeks bony tenderness was absent in all the cases. The most common complication observed was superficial infection(8.57%) delayed union (8.57%) and joint stiffness (8.57%). Mal-union (5.71%) and shortening of limb (5.71%) were noticed in few cases. In our study, no case of implant failure was found. Hospital stay of the patients ranged from 1 to 6 weeks. Most of the patients (62.86%) stayed for 1 to 3 weeks duration.

CONCLUSION

In conclusion, locking compression plate is a safe and sound fixation system for the treatment of fracture of the long bones. The rate of union as well as range of motion makes it a good treatment option. It is the implant of choice in case of osteoporotic, pathological, comminuted, periarticular and periprosthetic fractures as well as very wide or very narrow medullary canal in fractured bone. LCP is an alternative choice of implants for conventional plating and intramedullary nailing. It takes minimal time and less blood loss when used as a MIPO technique. The fixation of the long bone fracture by LCP allowed rapid mobilization and early weight bearing and does not interfere with functional use of limb during treatment or healing of fracture.

So it can be said that, if preoperative planning and biomechanical principles are followed, LCP provide excellent fixation in difficult situations.

REFERENCES

1. A.R. Saied and M. Karimi Mobarke: Epidemiology Magnus Bjo rkenheim, Jarko pajarinen and Vesa Savolain: Internal fixation of proximal humeral fractures with a locking compression plate: Acta Ortho Scand 2004:75(6): 741-745.
2. Anderson LD, Sisk D, Tooms RE, park WI III. Arota R, Lutz M, Zimmermann R, Krappinger D, Espen D, Gabi M. Complications following internal fixation of unstable distal radius fracture with a palmer locking plate. J Orthop Trauma. 2007;21:316-22.
3. C. Kanchanomai, V. phiphobmongkol, p. Muanjan, Fatigue failure of an orthopedic implant-A locking compression plate, Engineering Failure Analysis 15(2008) 521-530.
4. Cautu RV. Koval KJ. The use of locking plates in fracture care. J Arm Acad Orthop surg. 2006; 14:183.90.
5. Danielle L. Miller, Tarun Goswami, A review of locking compression plate biomechanics and their advantages as internal fixators in fracture healing, Clinical Biomechanics 22 (2007) 1049-1062.
6. Justin M. UHL, Bemard Seguin, amy S. Kapatkin Kurt S. Schulz, Tanya C. Garica, Susan M. Stover, Mechanical Comparison of 3.5mm Broad Dynamic Compression plate, Broad Limited-Contact Dynamic Compression plate, and Narrow Locking Compression plate Systems Using Interfragmentary Gap Models, Veterinary Surgery 37:663-673,2008.
7. S. Terry Canale and James H. Beaty: Campbell's operative Orthopaedics, publisher mosby Elsevier, 2008, 11th edi; vol 3, p-3060,3175.
8. S.L. Ezekiel Tan, Zsolt J. Balogh, Indications and limitations of locked plating, Injury, Int. J. Care Injured 40 (2009)683-691.

Evaluation of Functional Outcome of Pre-Contoured Olecranon Locking Plate in Fractures of the Olecranon

Md. Mohtashemul Haque[1], Dr. Nilabh Kumar[2]

ABSTRACT

Objective: Present study aims to evaluate the functional outcome of precontoured olecranon locking plate for fractures of the olecranon.

Design: Consecutive case series.

Setting: Tertiary center

Patients: The study was performed on thirty one skeletally mature patients with displaced fractures of the olecranon.

Intervention: Open reduction and internal fixation of displaced olecranon fracture of ulna with pre contoured olecranon locking plate.

Main Outcome Measurements: Patients were assessed by measuring the range of motion and Mayo Elbow Performance Score (MEPS) and index (MEPI). Serial radiographs were reviewed preoperatively for fracture classification and associated fractures, immediately postoperatively, and at the time of final review for adequacy and maintenance of reduction, evidence of union and arthritis.

Results: At 1 year of follow up the mean flexion of elbow was 123.7° (range 90-130°), while the mean extension was 5.64° (range 0-30°). The MEPS index showed 1patient having fair result, 6 patients having good results and 24 patients having excellent results. None of the patients had poor results. The mean MEPS were 90.65. All patients showed full radiological union.

Conclusions: 'Pre-contoured Olecranon Locking Plate' provides rigid internal fixation allowing vigorous early mobilization at the elbow, especially in comminuted fractures of the olecranon. It shows an excellent rate of radiological union. There was no case of implant failure in our study, even in comminuted fractures, which can be attributed to the use of locking compression plates. Thus it is a viable alternative to other forms of fixation of olecranon fractures and is a versatile implant which can be used in all types of olecranon fractures with minimal complication rate.

KEY WORDS : Olecranon fracture; Pre contoured olecranon locking plate; Tension band wiring; Osteosynthesis

INTRODUCTION

Olecranon fractures accounts for approximately 10% of fractures around the elbow and 2% of all fractures of the upper limb. Olecranon fracture can be caused by direct trauma such as fall on the elbow or by indirect trauma such as falling on partially flexed elbow, with indirect forces by the triceps muscle avulsing the olecranon. Olecranon fractures can occur at any age but are most common in the first three decades of life while fractures of the proximal ulna occur predominantly in older patients. Nowadays, operative treatment is the management of choice for all displaced olecranon fractures. Fractures of the olecranon being intra-articular, and since the olecranon effectively functions as the fulcrum of the lever arm of the elbow, it is necessary to restore precise anatomical alignment and articular congruity with rigid fixation, so that early movement can be encouraged.

For long, tension band wiring was considered the gold standard for the treatment of minimally displaced and comminuted fractures of the olecranon with low levels of pain. However in comminuted fractures with bone loss results are far from satisfactory such as initiating early movement and contraction of sigmoid notch. Subchondral bone comminution opposite the tension-band construct may cause failure in compression.

According to a biomechanical study, a significantly more stable fixation was achieved by plate fixation in comminuted osteotomies and hence allowing early mobilisation. Moreover, locking compression plates provide superior mechanical stability at the fracture line because they provide angular stability. Further, locking screws have been shown to provide excellent stability even with unicortical purchase. Recent studies have shown the pre-contoured olecranon locking plate to be more effective with a lower rate of symptomatic hardware and subsequent implant removal than tension band wiring.

The purpose of this study is to evaluate the clinical results and functional outcome, and complications of management of olecranon fractures with the Pre-contoured Olecranon Locking Plate.

MATERIALS AND METHODS

Thirty one skeletally mature patients with displaced fractures of the olecranon who presented to the orthopedic emergency and the Out-Patient Department of Orthopaedics Katihar Medical College & Hospital, Katihar, Bihar were included in the study. Undisplaced fractures of the olecranon, patients with local infection or soft tissue defects around the fracture site and patients with poor general condition were not included in our study. The average age of the patients was 33.68 years (range, 22 to 56 years). Out of the 31 patients in the study, 21(68%) were male, and 10(32%) were female. The most common mode of injury was fall from stairs/ height on their elbow or outstretched arm which amounted to 20 cases (64.5%). Road traffic accidents were responsible in 11(35.5%) cases. The

1. M.S. (Ortho.), Assistant Professor, Department of Orthopaedics, K.M.C.H., Katihar, Bihar.
2. M.S. (Ortho.) Student, Junior Resident [Academic], Department of Orthopaedics, K.M.C.H., Katihar, Bihar.



MAYO CLASSIFICATION

dominant hand was involved in 19 out of the 31 patients.

The Mayo Classification was used to classify the fracture pattern. Type I fractures are undisplaced and stable, type II are displaced and unstable fractures but with intact collateral ligaments preventing dislocation and in type III fractures the elbow joint is unstable. Type II and III fractures are further subdivided into A (non-comminuted) and B (comminuted). Out of the 31 patients, 15(48.4%) had type IIA fractures while 13(42%) patients had type IIB fractures. Type III fractures were uncommon with 1(3.2%) patient having type IIIA and 2(6.4%) patients having type IIIB fractures. Patients having type I undisplaced fractures were not included in the study.

The surgery was performed under regional anesthesia with sedation or general anesthesia. All patients were placed in lateral decubitus position. Under tourniquet control, a posterior midline incision was given with a slight lateral curve at the point of the elbow. The fracture was temporarily fixed with K- wires. Then, a longitudinal slit was made in the triceps tendon to allow for optimal positioning of the plate over the tip of the olecranon. The plate of appropriate size was placed in position and held with the help of clamps. The plate was then fixed with the help of bicortical locking/non-locking screws [illegible] bicortical screws in the proximal fragment. Finally, a 'home-run screw' was passed from the apex of the olecranon crossing the fracture towards the base of the coronoid. Additional K-wires were used for inter-fragmentary fixation in cases of severe comminution. The stability of the fixation checked intra-operatively.

The elbow was splinted with an above-elbow plaster slab in the post-operative period. Guarded passive and assisted-active range of motion exercises were started on the 5th post-operative day. The plaster slab was removed at suture removal on the 14th post-operative day and range of motion exercises were continued. The patients were followed up serially at 3, 6, 12 weeks, 6 months and 1 year. All patients were followed up for a minimum of 1 year.

Patients were assessed by measuring the range of motion and Mayo Elbow Performance Score (MEPS) and index (MEPI). The MEPS measures range of motion, pain, elbow stability and ability to do activities of daily living. Serial radiographs were reviewed preoperatively for fracture classification and associated fractures,immediately postoperatively, and at the time of final reviewfor adequacy and maintenance of reduction, evidenceof union and arthritis.

RESULTS

The mean duration of surgery was 64.5 minutes (range 45-90 min). It was found that with increasing grades of Mayo classification, the duration of surgery increased. At one year of follow up, the mean flexion at the elbow at final follow up of 1 year was 123.7° (range 90-130°),while the mean extension at the elbow at 1 year was 5.64° (range 0-30°).The MEPS index at one year of follow up showed 1(3.2%) patient having fair result, 6(19.4%) patients having good results and 24(77.4%) patients having excellent results. None of the patients had poor results. The mean MEPS at 1 year of final follow up was 90.65.

A negative correlation was found between MEPS at 1 year and Mayo classification; that is higher grades of Mayo classification had lower MEPS scores compared and vice versa. A negative correlation was found between the day of surgery following injury and MEPS at 1 year; that is the later the day of surgery following injury the lesser the MEPS at 1 year. The mean MEPS of patients operated within 10 days was 93.2 compared the mean MEPS of patients operated after 10 days which was 82.5.

Reduction was maintained until union in all thirty one patients. The average time for radiological union ranged from 6 to 12 weeks with an average time of 10 weeks. Out of the 31 patients, 4(12.9%) patients had delayed union. Ultimately all patients showed full radiological union at follow up of 1 year and there was no case of non-union.

Out of the 31 patients, 1(3.2%) patient had superficial infection which was managed with wound debridement and intravenous antibiotics. The superficial infection healed uneventfully within a few days. 1(3.2%) of the patients had prominent implant causing skin impingement and may require implant removal at a later date. 1(3.2%) of the patients had chronic pain for over 6 months with restriction of motion at the elbow (ROM 30-90°). This patient had an open comminuted fracture of the olecranon and was operated 44 days after the injury.

DISCUSSION

The aim of operative treatment of fractures of the olecranon is restoration of the articular congruity of the ulno-humeral joint with rigid fixation, so that early mobilization of the elbow and rehabilitation can be initiated. 31 patients with fractures of the olecranon were treated by open reduction and internal fixation with the 'Pre-contoured Olecranon Locking Plate'. Only closed fractures were included in the study.

All the 31 fractures in the study showed radiological union at follow up. The average time for radiological union was 10 weeks with a range from 6 to 12 weeks. At 12 weeks all fractures had united except in 4 patients. Ultimately all fractures united at 1 year of follow up.In a study by Meredith L. Anderson et al, of the 32 patients treated with congruent elbow plate fixation, 30 achieved radiographic union. The average time to radiological union was 11.6 weeks. In another Seibenlist S et al, in 15 patients with fractures of the olecranon who underwent locking plate ostoesynthesis, the mean time to union was 11 weeks. In a study by Donald Macko et al, in 20 patients treated with TBW, 60% of the fractures healed by 12 weeks, 90% by 5 months and 95% by 7 months which was significantly later than our study.

The average elbow range of motion at 1 year of follow up was from 5.64° (0-30°) to 123.7° (90-130°). The average arc of motion was 118.06° at the end of 1 year of follow up. 26 of the 31 patients in our group had an extension deficit of 10° or lesser while only 5 patients had an extension deficit of more than 10°. Similarly only 5 patients had a flexion of lesser than 120°. In a study by Meredith L Anderson et al on 32 patients with olecranon fractures treated with Mayo Congruent Elbow Plating System, the mean range of motion at final follow up was 120° which was similar to our study. The mean extension deficit was 13.6° in their study.

In another study by Geert Buijze et al, the mean range of motion was 123° with an extension deficit of 13° In another study by RamazanErdenErturer et al, the mean range of motion was 116°. In a study by Mary C Hume et al, comparing the results of fracture fixation by TBW and One-third Tubular Plating, the mean extension deficit in the TBW group was 10° and 7° in the plating group.

The **MEPS (Mayo Elbow Performance Score)** was used because it emphasizes on the more important patient outcome factors such as pain, range of motion and whether the patient is able to do his activities of daily living. In our study, the mean MEPS at 1 year of follow up were 90.65. Of the 31 patients in our study, 24(77.4%) patients showed excellent results, 6(19.4%) patients showed good results and 1(3.2%) patient showed fair result. None of the patients had poor results at final follow up. In a study by Byron E Chalidis et al on treatment of olecranon fractures with TBW, 85.5% patients had good to excellent results compared to the 96.8% in our study, with 9.7% having fair result and 4.8% having poor results. In a study by Christopher S Bailey et al on the outcomes of plate fixation, 13(52%) patients had excellent results, 10(40%) good, (4%) fair and 1(4%) poor result. Meredith L Anderson in his study reported an average MEPS of 89, with 92% having good or excellent results. Seibenlist S in his study on pre-contoured locking plate osteosynthesis reported a mean MEPS of 97, with excellent results in 12 patients, good results in 2 patients and fair in 1 patient. Hence, it appears that MEPS scores are better in patients who undergo plating than in patients who undergo TBW. This may be due to the more rigid fixation which permits more vigorous and early mobilization of the elbow.

Complications were observed in 3 of the 31 patients. One patient developed superficial infection which healed uneventfully with debridement and IV antibiotics. Symptomatic implant prominence was seen in 1 patient causing impingement of the overlying skin and is awaiting implant removal. Donald Macko in his study on the complications of TBW in olecranon fractures reported a high rate of hardware prominence in 16 of his 20 patients. In a study by Byron E Chalidis on TBW in olecranon fractures, hardware removal was recorded in 82% of the patients. Seibenlist S in his study on pre-contoured locking compression plates reported hardware prominence leading to implant removal in 1 of the 15 patients. Meredith L Anderson in his study on 32 patients reported hardware prominence in 3 patients. On the basis of the above mentioned results, it can be concluded that the Pre-contoured olecranon locking plate has a low rate of hardware prominence. Chronic pain was reported in 1 of our patients. This patient presented to us more than 1 month after the injury and was operated 44 days following the injury. The patient also had restriction of movement at the elbow with a mean range of 60° (30°-90°). In a study by Christopher S Bailey on 25 patients who underwent plate fixation, 3 patients reported of chronic pain at the elbow.: There were no other complications in our study such as myositis ossificans, implant failure, ulnar neuropathy which have been reported in previous studies.

CONCLUSION

Thus, we can conclude that the 'Pre-contoured Olecranon Locking Plate' provides rigid internal fixation allowing vigorous early mobilization at the elbow, especially in comminuted fractures of the olecranon which is necessary to achieve a good and fully functional elbow. It shows an excellent rate of radiological union. There was no case of implant failure in our study, even in comminuted fractures, which can be attributed to the use of locking compression plates. There was a very minimal rate of complications in wound healing and due to implant prominence, in spite of the olecranon being a subcutaneous bone.We can conclude that, the 'Pre-contoured Olecranon Locking Plate' seems to be a viable alternative to other forms of fixation of olecranon fractures. We feel that it is a more versatile implant which can be used in all types of olecranon fractures with minimal complication rate.

REFERENCES

1. Rommens PM, Kuchle R, Schnieder RU et al. Olecranon fracture in adults, factors influencing outcome. Injury 2004, 35:1149-1157.
2. Ernest M Dalat. Fractures of the olecranon. Fracture Service of the Massachusetts General Hospital, 2004.
3. Duckworth AD, Clement ND, Atken SA et al. Epidemiology of fractures of the proximal ulna. Injury 2012, March 43(3): 343-346.
4. Jossefson PO, Johnell O, Gentz CF. Dislocations of the elbow and intrarticular fractures. Clinical Orthopaedics 1989 Jun 246: 126-130.
5. M. Ikeda, Y. Fukushima, Y. Kobayashi, Y. Oka. Comminuted fractures of the olecranon. Journal of Bone Joint Surgery [Br] 2001;83-B:805- 808.
6. Byron E Chalidis, Nick C Sachinis, Efthimios P Samoladas et al. Is tension band wiring technique the "gold standard" for the treatment of olecranon fractures? A long term functional outcome study.Journal of Orthopaedic Surgery and Research 2008 Feb, 3: 9, 1.
7. RamazanErdenErturer, Cem Sever, Mehmet MesutSonmez et al. Results of open reduction and plate osteosynthesis comminuted fracture of the olecranon. Journal of Shoulder Elbow Surgery 2011; 20: 449-454.
8. D.S. Newman, C. Mauffrey, S. Krikler et al. Olecranon Fractures. Injury, Int. J. Care Injured 2009; 40: 575–581.